

Nasopharyngeal Cancer and the Southeast Asian Patient

CHENG HER, M.D., University of Wisconsin Medical School, Madison, Wisconsin

Because of a documented increased incidence, nasopharyngeal cancer should be considered when signs or symptoms of ear, nose and throat disease are present in patients from southern China (in particular, Hong Kong and the province of Guangdong) or Southeast Asia. Environmental factors, the Epstein-Barr virus and genetic factors have been associated with the development of nasopharyngeal cancer. Patients with this malignancy most often present with a cervical mass from metastatic spread to a lymph node. Other possible presentations include ipsilateral serous otitis, hearing loss, nasal obstruction, frank epistaxis, purulent or bloody rhinorrhea, and facial neuropathy or facial nerve palsies. Radiotherapy is often curative. The addition of chemotherapy has produced high response rates in local and regionally advanced disease. (Am Fam Physician 2001;63:1776-82,1785.)

▶ A patient information handout on nasopharyngeal cancer, written by the author of this article, is provided on page 1785.

Members of various family practice departments develop articles for "Problem-Oriented Diagnosis." This article is one in a series coordinated by the Department of Family Medicine at the University of Wisconsin Medical School, Madison. Guest editor of the series is William E. Scheckler, M.D.

Although nasopharyngeal cancer is rare in the general U.S. population, it is significantly more likely to occur in refugees from Southeast Asia who have come to the United States in the past 25 years. Once diagnosed, the malignancy has great potential for cure. This article provides a brief overview of nasopharyngeal cancer, with emphasis on its occurrence in patients from Southeast Asia.

Illustrative Case

A 47-year-old Hmong man presented to his family physician with bloody rhinorrhea, epistaxis, right-sided hearing loss and headache of two weeks' duration. (The Hmong, also known as the Miao or Meo, are mountain-dwelling peoples of China, Vietnam, Laos and Thailand.) The patient's medical history was remarkable for colon cancer at 36 years of age, which evidently responded to Hmong therapies (nonsurgical). There was no family history of cancer. The patient had never smoked;

he used alcohol rarely and did not use illicit drugs. The patient's family had fled from Laos to the United States in the mid-1970s.

The review of systems was remarkable only for fatigue in the previous few weeks. The physical examination revealed right middle ear effusion, right hemifacial and periauricular hyperesthesia, and a trace of mucoid, bloody discharge in the nares. Neither cervical nor clavicular adenopathy was present.

Subsequent endoscopic biopsy of the right nasopharynx demonstrated mixed keratinizing squamous cell carcinoma and nonkeratinizing squamous cell carcinoma. Magnetic resonance imaging (MRI) showed a right nasopharyngeal mass with erosion into the sphenoid sinus.

Nasopharyngeal cancer was diagnosed and determined to be stage III (T3 N0: tumor invasion into the bony structures and/or paranasal sinuses; no regional lymph node metastasis). The patient underwent concurrent chemotherapy and radiotherapy; he experienced postirradiation headache and facial neuropathy. One year later, follow-up MRI studies showed nearly complete tumor regression.

Epidemiology

Nasopharyngeal cancer accounts for fewer than 1 percent of malignancies in North America, western Europe and Japan, with

Nasopharyngeal cancer is rare in the general U.S. population. It is significantly more likely to occur in persons of southern Chinese heritage and in refugees who have come to the United States from Southeast Asia.

TABLE 1
Average Incidence of Nasopharyngeal Cancer by Geographic Area

<i>Geographic area</i>	<i>Average number (range) of cases per 100,000 population per year</i>	<i>Average percentage of total cases per year</i>
Southern China (particularly Hong Kong and Guangzhou [formerly Canton])*	80 (10 to 150)	61
Alaska and Greenland	18 (15 to 20)	13
Northern China	7 (5 to 9)	5
Mediterranean basin (southern Italy, Greece and Turkey)	7 (5 to 9)	5
North Africa	7 (5 to 9)	5
Southeast Asia (Thailand, Vietnam, Indonesia, Malaysia and Singapore)	7 (5 to 9)	5
North America, western Europe and Japan	1 (1 to 1.5)	1

*—For persons of southern Chinese heritage who were born in the West, the average incidence of nasopharyngeal cancer is seven cases per 100,000 population per year; these persons account for 5 percent of nasopharyngeal cancers annually.

Information from Collins SL. Squamous cell carcinoma of the oral cavity and oropharynx. In: Ballenger JJ, Snow JB Jr, eds. *Otorhinolaryngology: head and neck surgery*. 15th ed. Media, Pa.: Williams & Wilkins, 1996:249-368, and Vasef MA, Ferlito A, Weiss LM. Nasopharyngeal carcinoma, with emphasis on its relationship to Epstein-Barr virus. *Ann Otol Rhinol Laryngol* 1997;106:348-56.

incidence rates of one to one and one-half cases per 100,000 population per year.¹ This malignancy has an intermediate incidence of five to nine cases per 100,000 population per year in inhabitants of northern China, the Mediterranean basin (southern Italy, Greece and Turkey), North Africa and Southeast Asia (Thailand, Vietnam, Indonesia, Malaysia and Singapore), and in persons of southern Chinese heritage who were born in the West (Australia, Hawaii and California). Among the Inuit in Alaska and Greenland, the incidence of nasopharyngeal cancer is increased to 15 to 20 cases per 100,000 population per year.^{1,2}

In southern China, particularly Hong Kong and Guangzhou (formerly known as Canton, and the capital of the province of Guangdong), nasopharyngeal cancer has a much higher incidence, with documented rates of 10 to 150 cases per 100,000 population per year (Table 1).^{1,2} Indeed, this malignancy is often referred to as “Cantonese cancer” or

“Kwangtung tumor.”¹ (Kwangtung is the old name for Guangdong, the province in which Guangzhou is located.)

Etiology and Pathogenesis

ENVIRONMENTAL FACTORS

The consumption of salted fish and other salt-preserved foods, including eggs, leafy vegetables and roots, in early childhood has been documented as a substantial risk factor for the development of nasopharyngeal cancer in Malaysian Chinese.³ Similarly, salted-fish consumption in early childhood has been correlated with an unusually high incidence of nasopharyngeal cancer in the boat communities of Hong Kong’s harbors.¹ *N*-nitrosodimethylamine in salted fish, perhaps in combination with vitamin deficiency, has been considered a likely carcinogen.^{1,3}

Occupational hazards, including exposures to formaldehyde, dust and smoke particulates, and certain aromatic hydrocarbons,

Most often, patients with nasopharyngeal cancer present with a cervical mass from metastatic spread to a lymph node.

have been investigated as risk factors for nasopharyngeal cancer.⁴⁻⁶ Tobacco and alcohol have also been examined as possible risk factors for this malignancy.^{3,4}

EPSTEIN-BARR VIRUS

Epstein-Barr virus, a herpesvirus, is the causative agent in acute infectious mononucleosis and is also associated with Hodgkin's disease, Burkitt's lymphoma, lymphoproliferative disease in the post-transplant setting, and T-cell lymphoma.^{1,2} Epstein-Barr virus initiates an early active (or lytic) infection; the virus then persists in a latent state until it is reactivated under certain conditions of immunosuppression or illness.

The link between nasopharyngeal cancer and Epstein-Barr virus was first observed in 1966, when the sera of patients with the malignancy were found to manifest precipitating antibodies against cells infected with the virus.⁷ Subsequent studies have described elevated levels of IgG and IgA antibodies directed against particular components of Epstein-Barr virus in patients with nasopharyngeal cancer.^{1,2}

GENETIC SUSCEPTIBILITY

Genetic susceptibility has also been proposed as a risk factor for the development of nasopharyngeal cancer. Haplotypes that have

been associated with the malignancy include certain human leukocyte antigens (HLA), including HLA-A2, HLA-B46 and HLA-B58.⁸

Diagnosis

HISTORY AND PHYSICAL EXAMINATION

A thorough history and a complete physical examination are essential in patients with ear, nose and throat complaints, especially patients from populations with an increased incidence of nasopharyngeal cancer.

Most often, patients with nasopharyngeal cancer present with a cervical mass from metastatic spread to a lymph node. Another common presenting sign is unilateral serous otitis as a result of eustachian tube occlusion by the primary tumor.² In some instances, digital examination in patients who have received a general anesthetic may localize a nodular lesion in the region of the eustachian tube orifice. Such tumors are often difficult to discern, however, as they can be small.

The presentation may also include nasal obstruction, frank epistaxis or purulent, bloody rhinorrhea, hearing loss (which may be temporarily relieved with autoinsufflation), tinnitus or headache. Patients with nasopharyngeal cancer may report facial hyperesthesia, paresthesia or dysesthesia, sometimes in the distribution of the second and third divisions of the trigeminal nerve. Cranial nerve infiltration with resultant palsy may also be present.^{2,9}

The differential diagnosis of nasopharyngeal cancer includes other nasopharyngeal or sinus masses (e.g., lymphoma, including Hodgkin's disease and lethal midline reticulosis), Wegener's granulomatosis and mucocele.

ENDOSCOPY

Further definition of the lesion or direct visualization of a nonpalpable but suspected lesion is possible with indirect nasopharyngoscopy or fiberoptic flexible or rigid endoscopy. Moreover, endoscopy allows a

The Author

CHENG HER, M.D., is a research fellow in the Department of Family Medicine at the University of Wisconsin Medical School, Madison, where he also completed a family medicine residency. Dr. Her received his medical degree from the University of Minnesota Medical School—Minneapolis.

Address correspondence to Cheng Her, M.D., Department of Family Medicine, University of Wisconsin Medical School, 777 S. Mills St., Madison, WI 53715-1896 (e-mail: cher@fammed.wisc.edu). Reprints are not available from the author.

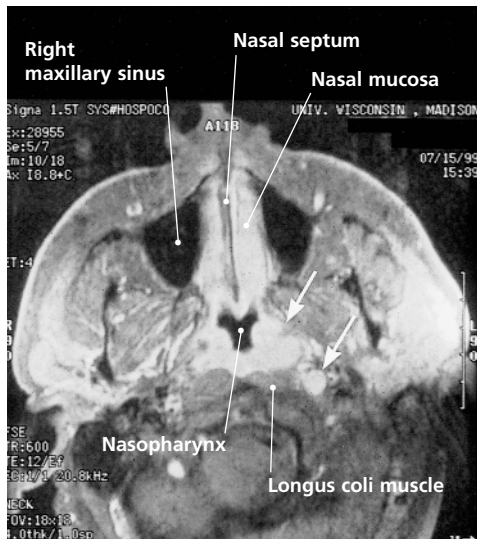


FIGURE 1. Sagittal magnetic resonance image in a patient with newly diagnosed squamous cell carcinoma of the nasopharynx. Arrows denote the primary tumor and a lateral retropharyngeal node metastasis. The patient was treated with high-dose radiation therapy and has been free of disease for two years.

biopsy to be performed.⁹ Endoscopy is felt to be essential to the work-up for nasopharyngeal cancer.

LABORATORY STUDIES

Although serologic testing for Epstein-Barr virus is not a diagnostic tool for nasopharyngeal cancer, it may be beneficial in some patients. Fine-needle aspiration and an enzyme-linked immunosorbent assay to identify Epstein-Barr virus genomes may be useful in patients who have cervical adenopathy but no discernible primary lesion.¹⁰⁻¹²

Tumor Assessment and Staging

TUMOR IMAGING

MRI is the modality of choice for the imaging of nasopharyngeal cancer^{9,13} (Figure 1). Chest radiography, hepatic ultrasonography and bone scanning may aid in the assessment of metastatic disease and, ultimately, the staging and treatment of this malignancy.¹⁴

TUMOR EXTENSION

Structures adjacent to the nasopharynx, such as nerves and vessels, facilitate the infiltration of nasopharyngeal cancer through foramina and fissures, from extracranial to intracranial spaces. Another mechanism of disease extension is direct invasion into the bone.^{1,9} Consequently, recognition of advanced disease is based on the degree of derangement of nasopharyngeal anatomy by the tumor mass, as well as the extent of tumor infiltration into surrounding tissue (Table 2).¹⁵

The presence of bulky cervical adenopathy is predictive of distant metastasis. Lungs, followed by bone, are the most common sites for metastasis.^{14,16-18}

STAGING

The American Joint Committee on Cancer and the International Union Against Cancer have developed staging systems for primary lesions based on the region of the nasopharynx that is involved.^{1,9,19} One investigator²⁰ developed another system for staging cervical metastases; this system has been adopted primarily in Hong Kong.

Treatment

Nasopharyngeal cancer has traditionally been treated with full-course radiotherapy. After appropriate radiotherapy, only about 10 to 20 percent of patient deaths are caused by local treatment failure.¹ Treatment results are more favorable in early stage disease.

Recent studies have demonstrated that concurrent chemotherapy and radiotherapy are effective in the treatment of local and regionally advanced nasopharyngeal cancer.^{14,16} In one study²¹ of concurrent chemotherapy and radiotherapy for patients with early stage (stage I and stage II) nasopharyngeal cancer, consistently high survival rates were documented. In this study, patients with stage I disease were treated with radiotherapy alone while patients with stage II disease

The treatment of choice for nasopharyngeal cancer is radiotherapy.

received concurrent chemotherapy and radiotherapy. Three-year disease-free survival rates were 91.7 percent for those with stage I disease and 96.9 percent for those with stage II disease.

Late-stage nasopharyngeal cancer (stage III and stage IV) demonstrated a three-year overall survival rate of 93 percent in another study²² of concurrent chemotherapy and

radiotherapy. In this study, all patients received concurrent chemotherapy and radiotherapy.

Similarly, neoadjuvant and adjuvant chemotherapy in local and regionally advanced disease has resulted in consistently high response rates.^{23,24} Nevertheless, distant metastases continue to impede improvement of survival rates for patients with nasopharyngeal cancer.

Final Comments

Since the mid-1970s, hundreds of thousands of refugees from Southeast Asia have been granted admittance to the United States as a direct result of their alliance with this

TABLE 2
Clinicopathologic Correlations in Nasopharyngeal Tumor Extension

The rightsholder did not grant rights to reproduce this item in electronic media. For the missing item, see the original print version of this publication.

country during the Vietnam War. These refugees constitute numerous groups, including, but not limited to, Vietnamese, Laotians and Cambodians, as well as a host of ethnic subgroups such as the Hmong.

Subsequent studies undertaken in the United States have developed data on the incidence of nasopharyngeal cancer in persons of Chinese origin and persons of Southeast Asian (non-Chinese) heritage.²⁵⁻²⁷ These data seem to correlate with results from previous studies. However, specific Southeast Asian ethnic subgroups (the Hmong, Karen and Akha, to name only three) are not well defined in the studies.

One possible explanation for this lack of data is that many Southeast Asian ethnic groups are reluctant to seek Western health care. Obviously, diseases are not reportable if patients do not volunteer complaints or do not allow themselves to be identified as ill. For the Hmong in particular, gruesome myths of torture and cannibalism at the hands of "American" physicians perpetuate a mentality of mistrust founded on misinformation and suspicion.

In addition, cancer registries and surveillance systems to date have been unable to further stratify "Asian/Pacific Islander" adequately. This could result in underreporting and, thus, underrepresentation of Southeast Asian ethnic subgroups that may be vulnerable to nasopharyngeal cancer.

Although many Southeast Asian ethnic groups claim genetic distinction from the Chinese and consequently may have less genetic susceptibility to nasopharyngeal cancer, the distinct possibility remains that environmental and virologic exposure among these ethnic groups mirror those of their southern Chinese neighbors. The relative proximity of Southeast Asia to southern China may have afforded similar exposures. Commercial and cultural interchanges (including intermarriage) within this shared geography may have resulted in exposure to similar insults (carcinogens and viruses).

It is important for family physicians to be aware of the possibility of nasopharyngeal cancer in Asians of Chinese heritage. Furthermore, although many Southeast Asian ethnic groups claim no genetic commonality with the Chinese, it is advisable to consider these groups to be at risk of nasopharyngeal cancer.

Figure 1 was provided by Paul M. Harari, M.D., associate professor of human oncology, University of Wisconsin-Madison.

The author thanks Michael McDonald, M.D., clinical associate professor in the Department of Surgery at the University of Wisconsin Medical School, Madison, for his review of the manuscript, and William E. Scheckler, M.D., professor in the Department of Family Medicine at the University of Wisconsin Medical School, for his support of the research. The author also thanks Stacy Her, M.D., for reviewing preliminary drafts of the manuscript.

REFERENCES

- Collins SL. Squamous cell carcinoma of the oral cavity and oropharynx. In: Ballenger JJ, Snow JB Jr., eds. Otorhinolaryngology: head and neck surgery. 15th ed. Media, Pa.: Williams & Wilkins, 1996:249-368.
- Vasef MA, Ferlito A, Weiss LM. Nasopharyngeal carcinoma, with emphasis on its relationship to Epstein-Barr virus. *Ann Otol Rhinol Laryngol* 1997;106:348-56.
- Armstrong RW, Imrey PB, Lye MS, Armstrong MJ, Yu MC, Sani S. Nasopharyngeal carcinoma in Malaysian Chinese: salted fish and other dietary exposures. *Int J Cancer* 1998;77:228-35.
- Farrow DC, Vaughan TL, Berwick M, Lynch CF, Swanson GM, Lyon JL. Diet and nasopharyngeal cancer in a low-risk population. *Int J Cancer* 1998;78:675-9.
- Vaughan TL, Stewart PA, Teschke K, Lynch CF, Swanson GM, Lyon JL, et al. Occupational exposure to formaldehyde and wood dust and nasopharyngeal cancer. *Occup Environ Med* 2000;57:376-84.
- Mirabelli MC, Hoppin JA, Tolbert PE, Herrick RF, Gnepp DR, Brann EA. Occupational exposure to chlorophenol and the risk of nasal and nasopharyngeal cancers among U.S. men aged 30 to 60. *Am J Ind Med* 2000;37:532-41.
- Old LJ, Boyse EA, Oettgen HF, dé-Harven E, Geering G, Williamson B, et al. Precipitating antibody in human serum to an antigen present in cultured Burkitt's lymphoma cells. *Proc Natl Acad Sci U S A* 1966;56:1699-704.
- Ren EC, Chan SH. Human leukocyte antigens and nasopharyngeal carcinoma. *Clin Sci [Colch]* 1996; 91:256-8.

Nasopharyngeal Cancer

9. Altun M, Fandi A, Dupuis O, Cvitkovic E, Krajina Z, Eschwege F. Undifferentiated nasopharyngeal cancer (UCNT): current diagnostic and therapeutic aspects. *Int J Radiat Oncol Biol Phys* 1995;32:859-77.
10. Feinmesser R, Miyazaki I, Cheung R, Freeman JL, Noyek AM, Dosch HM. Diagnosis of nasopharyngeal carcinoma by DNA amplification of tissue obtained by fine-needle aspiration. *N Engl J Med* 1992;326:17-21.
11. Smith SS, Fowler LJ, Hausenfluke L, Cho CG, Eagan PA, Gulley ML. Diagnosis of Epstein-Barr virus associated nasopharyngeal carcinoma using fine-needle aspiration biopsy and molecular diagnostics. *Diagn Cytopathol* 1995;13:155-9.
12. Shotelersuk K, Khorprasert C, Sakdikul S, Pornthanakasem W, Voravud N, Mutirangura A. Epstein-Barr virus DNA in serum/plasma as a tumor marker for nasopharyngeal cancer. *Clin Cancer Res* 2000;6:1046-51.
13. Ng SH, Wan YL, Ko SF, Chang JT. MRI of nasopharyngeal carcinoma with emphasis on relationship to radiotherapy. *J Magn Reson Imaging* 1998; 8:327-36.
14. Geara FB, Sanguineti G, Tucker SL, Garden AS, Ang KK, Morrison WH, et al. Carcinoma of the nasopharynx treated by radiotherapy alone: determinants of distant metastasis and survival. *Radiother Oncol* 1997;43:53-61.
15. Ortiz McWilliams JA. History and physical examination. In: Myers EM, ed. *Head and neck oncology: diagnosis, treatment, and rehabilitation*. Boston: Little, Brown, 1991:19-42.
16. Cheng SH, Jian JJ, Tsai SY, Chan KY, Yen LK, Chu NM, et al. Prognostic features and treatment outcome in locoregionally advanced nasopharyngeal carcinoma following concurrent chemotherapy and radiotherapy. *Int J Radiat Oncol Biol Phys* 1998;41:755-62.
17. Geara FB, Glisson BS, Sanguineti G, Tucker SL, Garden AS, Ang KK, et al. Induction chemotherapy followed by radiotherapy versus radiotherapy alone in patients with advanced nasopharyngeal cancer: results of a matched cohort study. *Cancer* 1997;79:1279-86.
18. Sanguineti G, Geara FB, Garden AS, Tucker SL, Ang KK, Morrison WH, et al. Carcinoma of the nasopharynx treated by radiotherapy alone: determinants of local and regional control. *Int J Radiat Oncol Biol Phys* 1997;37:985-96.
19. Cooper JS, Cohen R, Stevens RE. A comparison of staging systems for nasopharyngeal carcinoma. *Cancer* 1998;83:213-9.
20. Ho JH. An epidemiologic and clinical study of nasopharyngeal carcinoma. *Int J Radiat Oncol Biol Phys* 1978;4(3-4):182-98.
21. Cheng SH, Tsai SY, Yen KL, Jian JJ, Chu NM, Chan KY, et al. Concomitant radiotherapy and chemotherapy for early-stage nasopharyngeal carcinoma. *J Clin Oncol* 2000;18:2040-5.
22. Cooper JS, Lee H, Torrey M, Hochster H. Improved outcome secondary to concurrent chemoradiotherapy for advanced carcinoma of the nasopharynx: preliminary corroboration of the intergroup experience. *Int J Radiat Oncol Biol Phys* 2000; 47:861-6.
23. Chan AT, Teo PM, Johnson PJ. Controversies in the management of locoregionally advanced nasopharyngeal carcinoma. *Curr Opin Oncol* 1998; 10:219-25.
24. Chan AT, Teo PM, Leung, TW, Johnson PJ. The role of chemotherapy in the management of nasopharyngeal carcinoma. *Cancer* 1998;82:1003-12.
25. Marks JE, Phillips JL, Menck HR. The National Cancer Data Base report on the relationship of race and national origin to the histology of nasopharyngeal carcinoma. *Cancer* 1998;83:582-8.
26. Miller BA, Kolonel LN, et al, eds. *Racial/ethnic patterns of cancer in the United States, 1988-1992*. Washington, D.C.: U.S. Department of Health and Human Services, National Institute of Health, 1996; NIH publication no. 96-4104.
27. Sutton JB, Green JP, Meyer JL, Louie D, Heltzel M, Karp AH. Nasopharyngeal carcinoma. A study examining Asian patients treated in the United States. *Am J Clin Oncol* 1995;18:337-42.