


# Evaluation and Management of Herpes Zoster Ophthalmicus

SAAD SHAIKH, M.D., and CHRISTOPHER N. TA, M.D.  
Stanford University Medical Center, Stanford, California

**Herpes zoster ophthalmicus occurs when the varicella-zoster virus is reactivated in the ophthalmic division of the trigeminal nerve. Herpes zoster ophthalmicus represents up to one fourth of all cases of herpes zoster. Most patients with herpes zoster ophthalmicus present with a periorbital vesicular rash distributed according to the affected dermatome. A minority of patients may also develop conjunctivitis, keratitis, uveitis, and ocular cranial-nerve palsies. Permanent sequelae of ophthalmic zoster infection may include chronic ocular inflammation, loss of vision, and debilitating pain. Antiviral medications such as acyclovir, valacyclovir, and famciclovir remain the mainstay of therapy and are most effective in preventing ocular involvement when begun within 72 hours after the onset of the rash. Timely diagnosis and management of herpes zoster ophthalmicus, with referral to an ophthalmologist when ophthalmic involvement is present, are critical in limiting visual morbidity. (Am Fam Physician 2002;66:1723-30,1732. Copyright© 2002 American Academy of Family Physicians.)**

 A patient education handout on HZO, written by the authors of this article, is provided on page 1732.

See page 1591  
for definitions of  
strength-of-evidence  
levels.

**H**erpes zoster is a common infection caused by the human herpesvirus 3, the same virus that causes varicella (i.e., chickenpox). It is a member of the same family (Herpesviridae) as herpes simplex virus, Epstein-Barr virus, and cytomegalovirus. Reactivation of the latent virus in neurosensory ganglia produces the characteristic manifestations of herpes zoster, commonly known as shingles. Normal aging, poor nutrition, and immunocompromised status correlate with outbreaks of herpes zoster, and certain factors such as physical or emotional stress and fatigue may precipitate an episode.

Herpes zoster ophthalmicus occurs when reactivation of the latent virus in the trigeminal ganglia involves the ophthalmic division of the nerve. The virus damages the eye and surrounding structures by secondary perineural and intraneural inflammation of sensory nerves.<sup>1</sup> Herpes zoster ophthalmicus repre-

sents approximately 10 to 25 percent of all cases of herpes zoster.<sup>2</sup> Although herpes zoster ophthalmicus most often produces a classic dermatomal rash, a minority of patients may have only ophthalmic findings, limited mainly to the cornea. Direct ocular involvement is not specifically correlated with age, gender, or severity of disease. Serious sequelae include chronic ocular inflammation, vision loss, and disabling pain.

## Extraocular Manifestations of Herpes Zoster Ophthalmicus

The prodromal phase of herpes zoster ophthalmicus includes an influenza-like illness with fatigue, malaise, and low-grade fever that lasts up to one week before the rash over the forehead appears.<sup>3</sup> About 60 percent of patients have varying degrees of dermatomal pain in the distribution of the ophthalmic nerve.<sup>4</sup> Subsequently, erythematous macules appear along the involved dermatome, rapidly progressing over several days to papules and vesicles containing clear serous fluid and, later, pustules. These lesions rupture and typically crust over, requiring several weeks to heal completely.<sup>5</sup>

Immunocompromised persons, particularly those with human immunodeficiency virus infection, have a much higher risk of

*Herpes zoster ophthalmicus occurs when reactivation of latent herpes zoster in the trigeminal ganglia involves the ophthalmic division of the nerve.*

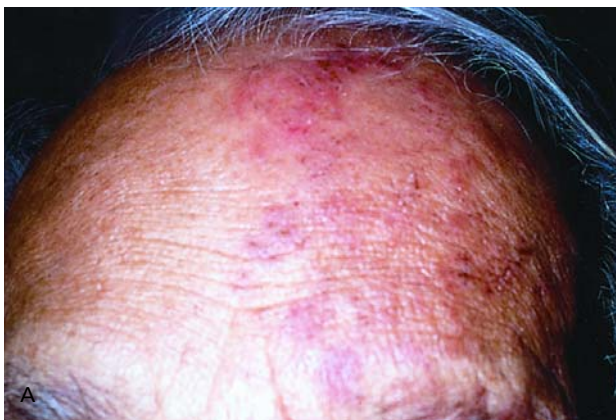developing herpes zoster ophthalmicus than the normal population.<sup>6</sup> These patients may have a generalized vesicular rash and become severely ill one to two weeks after disease onset. In addition, such patients develop more serious visual sequelae.<sup>7</sup>

Viral transmission from patients with herpes zoster can occur, but it is less frequent than transmission from patients with chick-

enpox.<sup>7</sup> Virus particles can be transmitted through direct contact with secretions from vesicles and secretion-contaminated articles.

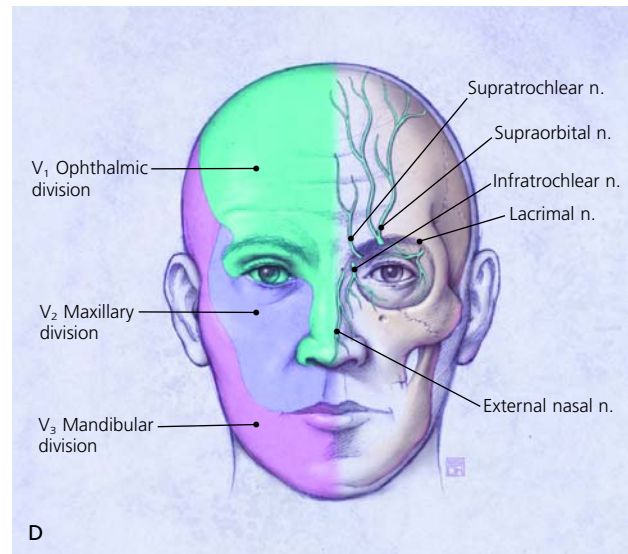
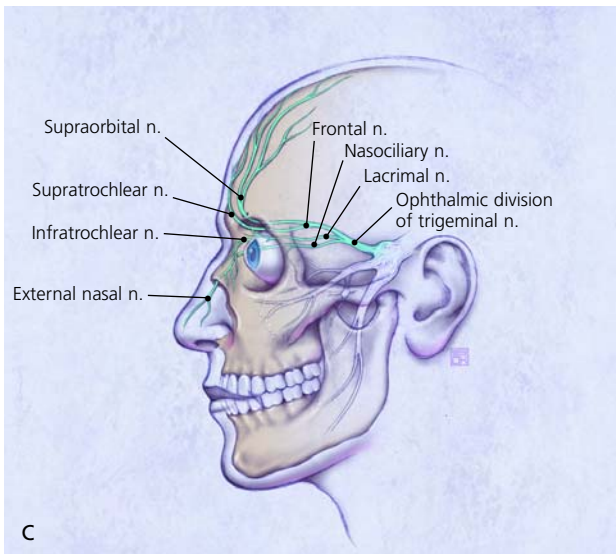
### Ocular Manifestations of Herpes Zoster Ophthalmicus

The skin manifestations of herpes zoster ophthalmicus strictly obey the midline with involvement of one or more branches of the



*The rightsholder did not grant rights to reproduce this item in electronic media. For the missing item, see the original print version of this publication.*

B



D

ILLUSTRATIONS BY STEVE OH

**FIGURE 1.** The hallmark of herpes zoster ophthalmicus is a vesicular rash that involves the first (ophthalmic) division of the fifth cranial nerve that presents in a dermatomal distribution and respects the midline (a). The upper eyelid is commonly involved with edema, inflammation, and resultant ptosis (b). The sensory distribution of the ophthalmic (V<sub>1</sub>) division of the trigeminal nerve (c,d).

**TABLE 1**  
**Ocular and Cranial Nerve Involvement in Herpes Zoster Ophthalmicus**

<i>Structure involved</i>	<i>Signs</i>	<i>Time of onset (onset of rash = Day 0)</i>
<b>Eyelid/conjunctiva</b>		
Blepharoconjunctivitis	Cutaneous macular rash respecting midline and involving eyelids Conjunctival edema/inflammation	Day 0 (preceded by dermatomal pain) Two to three days
Secondary <i>Staphylococcus aureus</i> infection	Vesicular lesions/crusting Yellowish crusting/discharge	Six days One to two weeks
<b>Episclera/sclera</b>		
Episcleritis/scleritis	Diffuse or localized redness, pain, and swelling	One week
<b>Cornea</b>		
Punctate epithelial keratitis	Swollen corneal surface epithelial cells	One to two days
Dendritic keratitis	"Medusa-like" epithelial defect with tapered ends	Four to six days
Anterior stromal keratitis (nummular keratitis)	Multiple fine infiltrates immediately beneath corneal surface	One to two weeks
Deep stromal keratitis	Deep stromal inflammation with lipid infiltrates and corneal neovascularization	One month to years
Neurotrophic keratopathy	Punctate corneal surface erosions Persistent epithelial defects Corneal ulcers	Months to years
<b>Anterior chamber</b>		
Uveitis	Inflammation and iris scarring	Two weeks to years
<b>Retina</b>		
Acute retinal necrosis/progressive outer retinal necrosis	Coalescent patches of retinal necrosis Occlusive vasculitis Vitreous inflammation (acute retinal necrosis only)	Independent/varied*
<b>Cranial nerves</b>		
Optic neuritis	Swollen, edematous optic nerve head	Independent/varied*
Oculomotor palsies	Extraocular motion abnormalities	Independent/varied*

\*—These syndromes may not be associated with acute herpes zoster ophthalmicus infection and/or can precede or follow at any time.

ophthalmic division of the trigeminal nerve, namely the supraorbital, lacrimal, and nasociliary branches (*Figure 1*). Because the nasociliary branch innervates the globe, the most serious ocular involvement develops if this branch is affected. Classically, involvement of the tip of the nose (Hutchinson's sign) has been thought

to be a clinical predictor of ocular involvement. Although patients with a positive Hutchinson's sign have twice the incidence of ocular involvement, one third of patients without the sign develop ocular manifestations.<sup>8</sup> A summary of ocular findings in patients with herpes zoster ophthalmicus is presented in *Table 1*.

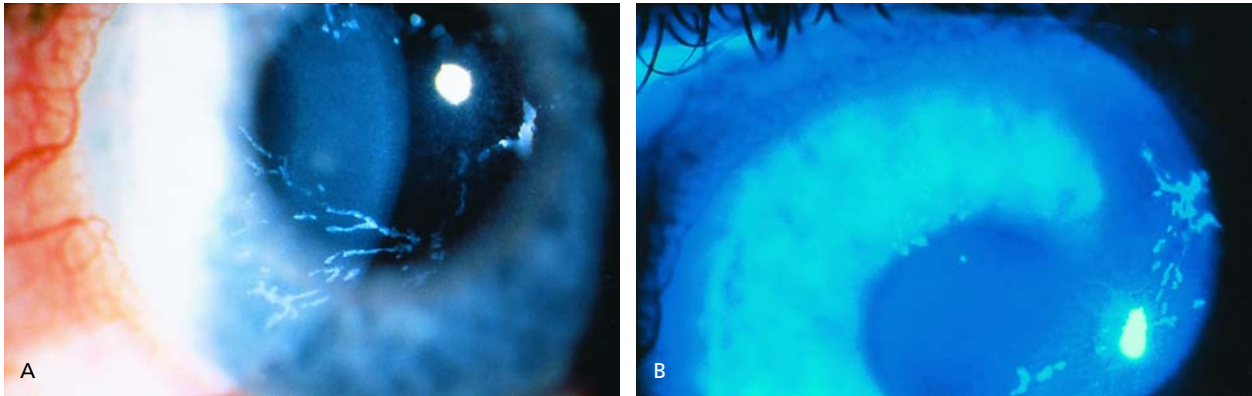


FIGURE 2. Slit lamp examination in a patient with herpes zoster ophthalmicus. Epithelial keratitis may have a dendritic appearance mimicking herpes simplex virus keratitis (a) and stains with fluorescein dye (b).

#### BLEPHARITIS AND CONJUNCTIVITIS

The eyelids are commonly involved in herpes zoster ophthalmicus (*Figure 1, part b*). Patients may develop blepharitis and present with ptosis secondary to edema and inflammation. A vast majority of patients will have vesicular lesions on the eyelids that resolve with minimal scarring.

Conjunctivitis is one of the most common complications of herpes zoster ophthalmicus. The conjunctiva appears injected and edematous, often with petechial hemorrhages.<sup>9</sup> The findings usually resolve within one week. However, secondary infection, usually *Staphylococcus aureus*, may develop and should be treated with broad-spectrum topical and/or systemic antibiotics.

#### CORNEAL DISEASE

Unlike eyelid or conjunctival involvement, corneal involvement can result in significant vision loss. The clinical features of corneal disease include direct viral infection, antigen-antibody reactions, delayed cell-mediated hypersensitivity reactions, and neurotrophic damage.<sup>7</sup> Patients with corneal disease present with varying degrees of decreased vision, pain, and light sensitivity. Corneal complications occur in approximately 65 percent of cases of herpes zoster ophthalmicus.<sup>7</sup>

**Epithelial Keratitis.** The earliest corneal finding is punctate epithelial keratitis.<sup>10</sup> On slit lamp examination, this appears as multiple, focal, swollen lesions that stain with rose bengal or fluorescein dye. These lesions probably contain live virus and may either resolve or progress to dendrite formation. Punctate epithelial keratitis may present as early as one or two days after the initial skin rash, while dendrites often present at four to six days but can appear many weeks later.<sup>11</sup>

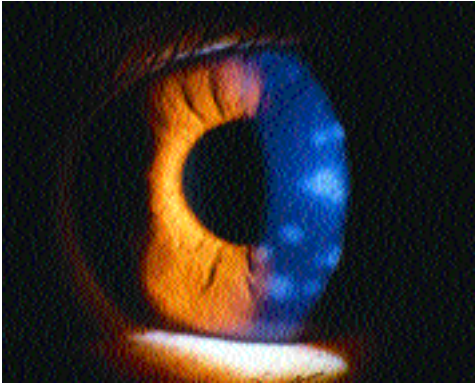
Herpes zoster virus dendrites appear as elevated plaques and consist of swollen epithelial cells. They form branching or “medusa-like” patterns and have tapered ends (*Figure 2, part a*) in contrast to herpes simplex virus dendrites, which often have terminal bulbs. Dendrites also stain with rose bengal and fluores-

#### The Authors

SAAD SHAIKH, M.D., is a vitreoretinal fellow at Associated Retinal Consultants, Royal Oak, Mich. He received his medical degree from the University of California, Davis, School of Medicine, and completed his residency in ophthalmology at Stanford University Medical Center, Stanford, Calif.

CHRISTOPHER N. TA, M.D., is an assistant professor in the Department of Ophthalmology at Stanford University School of Medicine. He received his medical degree from the University of Minnesota Medical School, Minneapolis. Dr. Ta completed his residency in ophthalmology at Stanford University Medical Center, and a fellowship in cornea and external diseases at the University of Texas in Dallas.

Address correspondence to Saad Shaikh, M.D., Associated Retinal Consultants, 3535 W. 13 Mile Rd., Suite 632, Royal Oak, MI 48073. Reprints are not available from the authors.



**FIGURE 3.** Slit lamp examination of a patient with nummular keratitis as a result of herpes zoster virus infection. Subepithelial infiltrates are located in the anterior stroma below areas of previous epithelial keratitis.

cein dye (*Figure 2, part b*) and can be viewed by Wood's lamp or slit lamp examination. Punctate and dendritic lesions can lead to anterior stromal corneal infiltrates.<sup>11,12</sup>

**Stromal Keratitis—Anterior Stromal Keratitis.** The earliest finding of corneal stromal involvement presents during the second week of disease, occurring in 25 to 30 percent of patients with herpes zoster ophthalmicus.<sup>13</sup> The condition, known as anterior stromal keratitis or nummular keratitis, is characterized by multiple fine granular infiltrates in the anterior corneal stroma below the epithelial layer (*Figure 3*). Most of the infiltrates lie directly beneath pre-existing dendrites or areas of punctate epithelial keratitis. The infiltrates are thought to arise from antigen-antibody interaction resulting from viral proliferation in the overlying epithelium.<sup>10,12</sup> Anterior stromal keratitis may be prolonged and recurrent.

**Stromal Keratitis—Deep Stromal Keratitis.** This later stage of stromal keratitis is relatively uncommon and typically develops three to four months after the initial acute episode, but development can range from one month to many years later.<sup>7</sup> It is usually central and preceded by anterior stromal keratitis. The keratitis may present as a lesion consisting of a localized area of inflammation

affecting all levels of the stroma, or as peripheral infiltrates that may have a surrounding immune ring. Corneal edema may be a prominent feature at this stage, usually with associated anterior chamber inflammation. A rare necrotizing form can also occur. A chronic relapsing course is not unusual, especially without timely and adequate treatment. Corneal neovascularization and lipid infiltrates may occur in patients with uncontrolled chronic disease. The pathogenesis of stromal disease probably involves a delayed cell-mediated hypersensitivity reaction.

**Neurotrophic Keratopathy.** Neurotrophic keratitis is the end result of decreased corneal sensation from herpes zoster virus-mediated destruction, including susceptibility to mechanical trauma, decreased lacrimation, and delayed epithelial healing.<sup>7</sup> Corneal thinning is a serious complication that may lead to corneal perforation. Such patients are at high risk for developing a secondary bacterial infection. Using preservative-free lubricating drops and ointment can prevent the development of epithelial defects.

#### UVEITIS

Anterior uveitis, which is diagnosed by slit lamp examination, refers to inflammation of the iris and ciliary body and occurs frequently with herpes zoster ophthalmicus. It may be isolated or associated with keratitis. The inflammation is generally mild and transient, but it frequently causes a mild elevation in intraocular pressure. Zoster uveitis can result in iris atrophy and an irregular pupil. As with stromal keratitis, the course of disease may be prolonged, especially without timely, adequate treatment. Herpes zoster uveitis may cause glaucoma and cataract formation. Chronic inflammation can lead to endothelial cell injury, resulting in corneal edema.

#### EPISCLERITIS AND SCLERITIS

Findings of episcleritis include localized or diffuse redness, as well as pain and swelling of the conjunctiva and episclera. Scleritis is a

*Increased age and prodromal symptoms are associated with a higher prevalence of postherpetic neuralgia.*

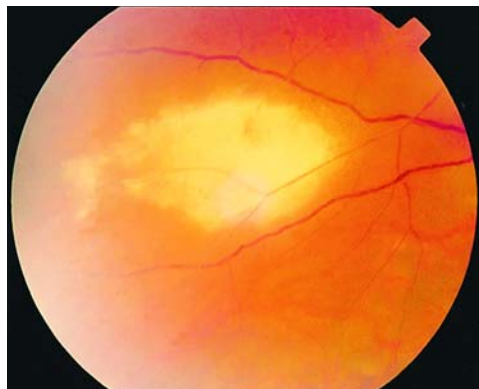

FIGURE 4. Zoster retinitis characterized by peripheral patches of retinal necrosis.

more serious condition with involvement of the sclera. Both conditions may be accompanied by localized stromal keratitis.

#### ACUTE RETINAL NECROSIS AND PROGRESSIVE OUTER RETINAL NECROSIS SYNDROMES

Herpes zoster virus is considered the offending agent in most cases of acute retinal necrosis and progressive outer retinal necrosis syndromes. Compared with acute retinal necrosis, progressive outer retinal necrosis is a more severe viral retinitis observed in immunocompromised persons, often in patients with acquired immunodeficiency syndrome.

Symptoms include blurred vision and/or pain in one or both eyes. Acute retinal necrosis is characterized by peripheral patches of retinal necrosis that rapidly coalesce (*Figure 4*), occlusive vasculitis, and vitreous inflammation. Conversely, immunocompromised patients with progressive outer retinal necrosis are unable to mount a vitreous inflammatory response, leading to rapid involvement of the macula. Both conditions commonly cause retinal detachment. The prognosis is extremely

*The rightsholder did not grant rights to reproduce this item in electronic media. For the missing item, see the original print version of this publication.*

FIGURE 5.

poor in patients with progressive outer retinal necrosis; most patients have no light perception vision.<sup>14</sup> The visual prognosis in patients with acute retinal necrosis is better, with many patients achieving a visual acuity of 20/40.<sup>15</sup> Bilateral involvement in both forms is observed in one third of patients but may be as high as 70 percent in patients with untreated disease.<sup>16</sup> Treatment includes long courses of oral and intravenous acyclovir (Zovirax), and corticosteroids.

#### Postherpetic Neuralgia and Other Neurologic Complications

Postherpetic neuralgia affects about 7 percent of patients and is characterized by varying degrees of constant or intermittent pain in the distribution of the affected dermatome.<sup>17</sup> Increased age and prodromal symptoms are associated with a higher prevalence of postherpetic neuralgia. It generally improves with time but may last for months to years. In severe cases, patients may be depressed and suicidal. Treatment includes topical capsaicin cream, over-the-counter analgesics, tricyclic antidepressants, and anticonvulsants.<sup>18</sup>

Cranial nerve palsies involving the third (most common), fourth, and sixth nerves may occur rarely (*Figure 5*). A majority of the cases will have spontaneous resolution within six months. Optic neuritis has been noted in about one in 400 cases and may precede reti-

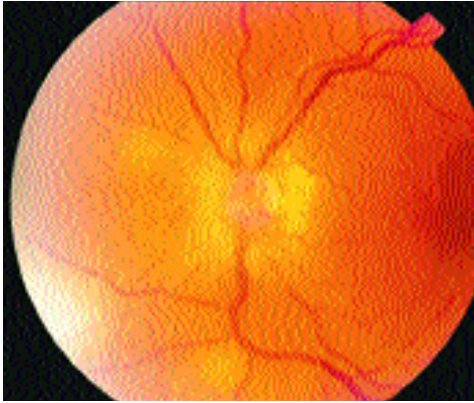


FIGURE 6. Edema and swelling of the optic nerve in a patient who had concomitant zoster retinitis.

nal disease or follow acute herpes zoster ophthalmicus infection (Figure 6).<sup>17,19,20</sup>

### Treatment of Herpes Zoster Ophthalmicus

Patients with herpes zoster ophthalmicus are treated with oral acyclovir (800 mg, five times daily) for seven to 10 days. Studies report alleviation of pain with oral acyclovir during the initial stages of the disease, especially if the drug is taken within the first three days of symptoms, and it may have a favorable effect on postherpetic neuralgia.<sup>21-23</sup> [Reference 22—Evidence level A, randomized controlled trial (RCT). Reference 23—Evidence level A, RCT] Additionally, acyclovir administered within 72 hours of onset has been found to speed resolution of skin lesions, reduce viral shedding, and decrease the incidence of dendritic and stromal keratitis as well as anterior uveitis.<sup>24,25</sup>

Valacyclovir (Valtrex) has higher bioavailability and has been shown to be equally safe and effective for the treatment of herpes zoster at a dosage of 1,000 mg three times daily for seven or 14 days.<sup>26</sup> [Evidence level A, RCT] Valacyclovir in a seven-day dosage regimen was recently shown to prevent ocular complications of herpes zoster ophthalmicus, including conjunctivitis, superficial and stromal keratitis, and pain.<sup>27</sup> [Evidence level A, RCT] Famciclovir (Famvir), 500 mg orally three times a day for seven days, may also be used.<sup>28</sup> Intravenous acyclovir is recommended in immunocompromised patients.<sup>29,30</sup> [Reference 29—Evidence level A, RCT] Acute pain control is achieved by local care and oral analgesics. Topical anesthetics should never be prescribed because of their

corneal toxicity. A summary of treatment and management options for various ocular manifestations of herpes zoster ophthalmicus is presented in Table 2.

The authors indicate that they do not have any conflicts of interest. Sources of funding: none reported.

TABLE 2  
Recommended Treatment of Varicella-Zoster Virus Infections

Infection	Treatment
Shingles*	Acyclovir (Zovirax), 800 mg orally five times daily for seven to 10 days
Skin	Palliative with cool compresses, mechanical cleansing
Blepharitis/conjunctivitis†	Palliative, with cool compresses and topical lubrication Topical broad-spectrum antibiotic indicated for secondary bacterial infection (usually <i>Staphylococcus aureus</i> )
Epithelial keratitis‡	Debridement or none
Stromal keratitis‡	Topical steroids
Neurotrophic keratitis‡	Topical lubrication Topical antibiotics for secondary infections Tissue adhesives and protective contact lenses to prevent corneal perforation
Uveitis‡	Topical steroids Oral steroids Oral acyclovir‡
Scleritis/episcleritis‡	Topical nonsteroidal anti-inflammatory agents and/or steroids
Acute retinal necrosis/ progressive outer retinal necrosis	Intravenous acyclovir (1,500 mg per m <sup>2</sup> per day divided into three doses) for seven to 10 days, followed by oral acyclovir (800 mg orally five times daily) for 14 weeks Laser/surgical intervention

\*—If fewer than seven days after onset for herpes zoster; most effective if fewer than 72 hours after onset in herpes zoster ophthalmicus.

†—Patients with manifestations of ocular involvement and/or complications of herpes zoster virus infection should be referred to an ophthalmologist for management.

‡—The use of oral acyclovir in cases of zoster uveitis remains controversial. Oral acyclovir may be beneficial as an adjunct to topical antivirals and topical steroids in severe cases of zoster keratouveitis.<sup>2,3</sup>

Adapted with permission from Arffa RC, Grayson M. Grayson's Diseases of the Cornea. 4th ed. St. Louis: Mosby, 1997, and with information from references 2 and 3.

### REFERENCES

1. Naumann G, Gass JD, Font RL. Histopathology of herpes zoster ophthalmicus. *Am J Ophthalmol* 1968;65:533-41.
2. Ragozzino MW, Melton LJ 3d, Kurland LT, Chu CP, Perry HO. Population-based study of herpes zoster and its sequelae. *Medicine* 1982;61:310-6.
3. Goh CL, Khoo L. A retrospective study of the clinical presentation and outcome of herpes zoster in a tertiary dermatology outpatient referral clinic. *Int J Dermatol* 1997;36:667-72.
4. Cobo M, Foulks GN, Liesegang T, Lass J, Sutphin J, Wilhelmus K, et al. Observations on the natural history of herpes zoster ophthalmicus. *Curr Eye Res* 1987;6:195-9.
5. Burgoon CF, Burgoon JS, Baldrige GD. The natural history of herpes zoster. *JAMA* 1957;174:265.
6. Sandor EV, Millman A, Croxson TS, Mildvan D. Herpes zoster ophthalmicus in patients at risk for the acquired immune deficiency syndrome (AIDS). *Am J Ophthalmol* 1986;101:153-5.
7. Baratz KH, Goins K, Cobo M. Varicella-zoster viral infections. In: Kaufman HE, ed. *The cornea*. New York: Churchill Livingstone, 1988.
8. Harding SP, Lipton JR, Wells JC. Natural history of herpes zoster ophthalmicus: predictors of postherpetic neuralgia and ocular involvement. *Br J Ophthalmol* 1987;71:353-8.
9. Arffa RC. Viral diseases. In: Arffa RC, Grayson M, eds. *Grayson's Diseases of the cornea*. 4th ed. St. Louis: Mosby, 1997.
10. Liesegang TJ. Corneal complications from herpes zoster ophthalmicus. *Ophthalmology* 1985;92:316-24.
11. Jones DB. Herpes zoster ophthalmicus. In: Golden B, ed. *Symposium on ocular inflammatory disease*. Springfield, Ill.: Thomas, 1974.
12. Marsh RJ. Herpes zoster keratitis. *Trans Ophthalmol Soc U K* 1973;93:181-92.
13. Womack LW, Liesegang TJ. Complications of herpes zoster ophthalmicus. *Arch Ophthalmol* 1983;101:42-5.
14. Engstrom RE Jr, Holland GN, Margolis TP, Muccioli C, Lindley JI, Belfort R Jr, et al. The progressive outer retinal necrosis syndrome. A variant of necrotizing herpetic retinopathy in patients with AIDS. *Ophthalmology* 1994;101:1488-502.
15. Blumenkranz M, Clarkson J, Culbertson WW, Flynn HW, Lewis ML, Young GA. Vitrectomy for retinal detachment associated with acute retinal necrosis. *Am J Ophthalmol* 1988;106:426-9.
16. Palay DA, Sternberg P Jr, Davis J, Lewis H, Holland GN, Mieler WF, et al. Decrease in the risk of bilateral acute retinal necrosis by acyclovir therapy. *Am J Ophthalmol* 1991;112:250-5.
17. Kanski JJ. Herpes zoster ophthalmicus. In: Kanski JJ, Nischal KK, Milewski SA, eds. *Ophthalmology: clinical signs and differential diagnosis*. Philadelphia: Mosby, 1999.
18. Stankus SJ, Dlugopolski M, Packer D. Management of herpes zoster (shingles) and postherpetic neuralgia. *Am Fam Physician* 2000;61:2437-48.
19. Lee MS, Cooney EL, Stoessel KM, Gariano RF. Varicella zoster virus retrobulbar optic neuritis preceding retinitis in patients with acquired immune deficiency syndrome. *Ophthalmology* 1998;105:467-71.
20. Gunduz K, Ozdemir O. Bilateral retrobulbar neuritis following unilateral herpes zoster ophthalmicus. *Ophthalmologica* 1994;208:61-4.
21. Peterslund NA. Management of varicella zoster infections in immunocompetent hosts. *Am J Med* 1988;85:74-8.
22. Morton P, Thomson AN. Oral acyclovir in the treatment of herpes zoster in general practice. *N Z Med J* 1989;102:93-5.
23. Huff JC, Bean B, Balfour HH Jr, Laskin OL, Connor JD, Corey L, et al. Therapy of herpes zoster with oral acyclovir. *Am J Med* 1988;85:84-9.
24. Liesegang TJ. Herpes zoster keratitis. In: Krachmer JH, Mannis MJ, Holland EJ, eds. *Cornea*. St. Louis: Mosby, 1997.
25. McGill J, Chapman C, Mahakasingam M. Acyclovir therapy in herpes zoster infection. A practical guide. *Trans Ophthalmol Soc U K* 1983;103(pt 1):111-4.
26. Beutner KR, Friedman DJ, Forszpaniak C, Andersen PL, Wood MJ. Valaciclovir compared with acyclovir for improved therapy for herpes zoster in immunocompetent adults. *Antimicrob Agents Chemother* 1995;39:1546-53.
27. Colin J, Prisant O, Cochener B, Lescale O, Rolland B, Hoang-Xuan T. Comparison of the efficacy and safety of valaciclovir and acyclovir for the treatment of herpes zoster ophthalmicus. *Ophthalmology* 2000;107:1507-11.
28. Tying SK. Efficacy of famciclovir in the treatment of herpes zoster. *Semin Dermatol* 1996;15(2 suppl 1):27-31.
29. Balfour HH Jr, Bean B, Laskin OL, Ambinder RF, Meyers JD, Wade JC, et al. Acyclovir halts progression of herpes zoster in immunocompromised patients. *N Engl J Med* 1983;308:1448-53.
30. Balfour HH Jr. Varicella zoster virus infections in immunocompromised hosts. A review of the natural history and management. *Am J Med* 1988;85:68-73.