

# Intertrigo and Secondary Skin Infections

MONICA G. KALRA, DO, *Methodist Health System of Dallas, Dallas, Texas*

KIM E. HIGGINS, DO, *Physician Senior Services, Dallas, Texas*

BRUCE S. KINNEY, DO, *Methodist Health System of Dallas, Dallas, Texas*

Intertrigo is a superficial inflammatory dermatitis occurring on two closely opposed skin surfaces as a result of moisture, friction, and lack of ventilation. Bodily secretions, including perspiration, urine, and feces, often exacerbate skin inflammation. Physical examination of skin folds reveals regions of erythema with peripheral scaling. Excessive friction and inflammation can cause skin breakdown and create an entry point for secondary fungal and bacterial infections, such as *Candida*, group A beta-hemolytic streptococcus, and *Corynebacterium minutissimum*. Candidal intertrigo is commonly diagnosed clinically, based on the characteristic appearance of satellite lesions. Diagnosis may be confirmed using a potassium hydroxide preparation. Resistant cases require oral fluconazole therapy. Bacterial superinfections may be identified with bacterial culture or Wood lamp examination. Fungal lesions are treated with topical nystatin, clotrimazole, ketoconazole, oxiconazole, or econazole. Secondary streptococcal infections are treated with topical mupirocin or oral penicillin. *Corynebacterium* infections are treated with oral erythromycin. (*Am Fam Physician*. 2014;89(7):569-573. Copyright © 2014 American Academy of Family Physicians.)

**CME** This clinical content conforms to AAFP criteria for continuing medical education (CME). See CME Quiz Questions on page 515.

Author disclosure: No relevant financial affiliations.

► **Patient information:** A handout on this topic is available at <http://familydoctor.org/familydoctor/en/diseases-conditions/intertrigo.html>.

Intertrigo is caused by cutaneous inflammation of opposing skin surfaces. It is more common in hot and humid environments and during the summer. Skin folds, including inframammary (*Figure 1*), intergluteal, axillary, and interdigital (*Figure 2*) areas, may be involved.<sup>1</sup> Intertrigo is more common in young and older persons secondary to a weakened immune system, incontinence, and immobility, although it can occur at any age.<sup>2-4</sup>

## Etiology and Predisposing Factors

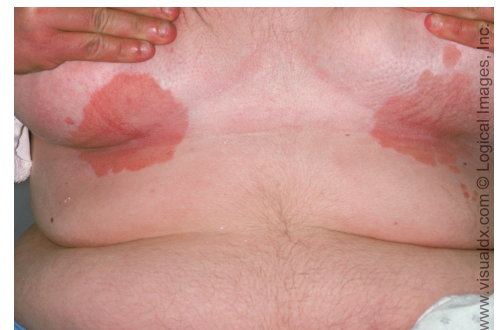Intertrigo most often occurs in patients with obesity (body mass index more than 30 kg per m<sup>2</sup>), diabetes mellitus, or human immunodeficiency virus infection, and in those who are bedridden. It also occurs in patients with large skin folds and those who wear diapers or other items that trap moisture against the skin. There is a linear increase in the severity of obesity and the presence of intertrigo.<sup>5</sup> Patients who are obese sweat more profusely because of their thick layers of subcutaneous brown fat, generating more heat than persons with normal body mass.<sup>6</sup> This increases thermal, frictional, and moisture components of the skin.<sup>5</sup>

As the stratum corneum becomes macerated because of hyperhydration, the friction intensifies and further weakens and damages the epidermal tissue. The condition can

progress to severe inflammation and skin breakdown. This erosion of the epidermal barrier may create an entry point for microorganisms that cause secondary infections.<sup>7</sup>

## Clinical Manifestations

Intertrigo is often a chronic disorder that begins insidiously with the onset of pruritus, stinging, and a burning sensation in skin folds. Physical examination of the skin folds usually reveals regions of erythema with peripheral scaling. Intertrigo associated with a fungal superinfection may produce satellite papules and pustules. Candidal intertrigo (*Figure 3*) is often associated with a foul-smelling odor. In the presence of a bacterial superinfection, plaques and abscesses may form.<sup>8</sup>



**Figure 1.** Inframammary intertrigo appearing as skin discoloration with no evidence of fungal or bacterial superinfection.

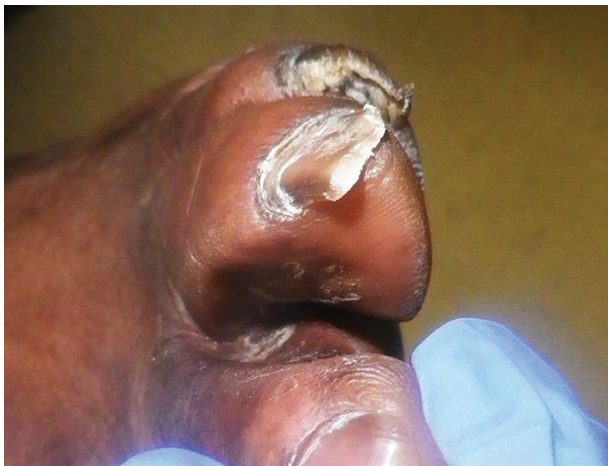Copyright © Logical Images, Inc.

**SORT: KEY RECOMMENDATIONS FOR PRACTICE**

Clinical recommendation	Evidence rating	References
Intertrigo associated with <i>Candida</i> should be managed with topical antifungals applied twice daily until the rash resolves.	C	14
Fluconazole (Diflucan), 100 to 200 mg daily for seven days, is used for intertrigo complicated by a resistant fungal infection. Patients who are obese may require an increased dosage.	C	14
Skin barrier protectants, such as zinc oxide ointment and petrolatum, as part of a structured skin care routine that also includes gentle cleansing and moisturizing may reduce recurrent intertrigo infections.	C	20, 21

A = consistent, good-quality patient-oriented evidence; B = inconsistent or limited-quality patient-oriented evidence; C = consensus, disease-oriented evidence, usual practice, expert opinion, or case series. For information about the SORT evidence rating system, go to <http://www.aafp.org/afpsort>.

Interdigital intertrigo (Figure 2) may be mild and asymptomatic, but also may lead to intense erythema and desquamation. The affected skin may have a foul odor and may be macerated and ulcerated with copious or purulent discharge. Patients with interdigital intertrigo and comorbidities such as obesity or diabetes are at greater risk of cellulitis.<sup>3</sup> Interdigital intertrigo can progress to a severe bacterial infection with pain, mobility problems, erysipelas, cellulitis, abscess formation, fasciitis, and osteomyelitis causing pain so severe that the patient is unable to ambulate.<sup>3</sup> Web space infections are typically caused by gram-positive cocci such as *Staphylococcus* and *Streptococcus* and may cause



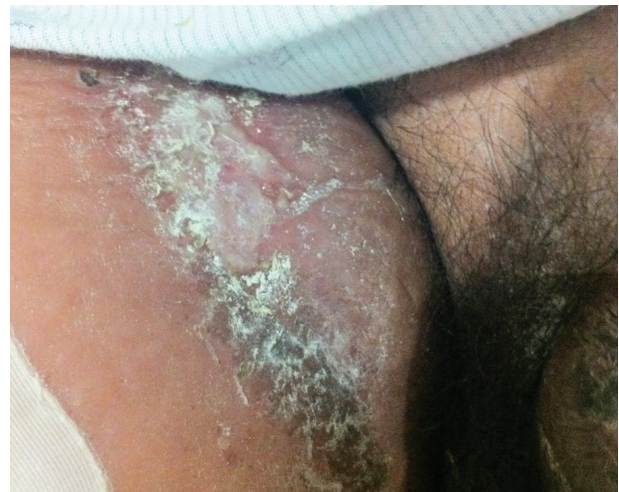**Figure 2.** Severe interdigital intertrigo with erythema suggestive of cellulitis.

ulceration, fever, and chills.<sup>9</sup> Foot care and patient education are key in preventing interdigital infections in patients with diabetes.<sup>10</sup>

**Diagnosis**

Intertrigo may be difficult to distinguish from other skin disorders, but the patient history will help in the diagnosis (Table 1).<sup>8</sup> The history should include previous treatments, especially topical steroids and antibacterial soaps or ointments. Some steroids may cause atrophy and maceration, and some soaps and ointments may exacerbate skin inflammation. A visual inspection of the skin will help identify lesions in other areas.<sup>8</sup>

The diagnosis of secondary fungal infections is commonly made clinically, based on the characteristic appearance and distribution of satellite papules and pustules.<sup>11</sup> The diagnosis may, however, be confirmed with a potassium hydroxide preparation positive for pseudohyphae and spores. Additionally, a potassium hydroxide preparation, Wood lamp examination, or culture of skin scrapings can diagnose conditions such as *Candida* or dermatophyte infections. The presence of hyphae on potassium hydroxide examination confirms dermatophytic lesions, including tinea versicolor and tinea corporis, and the presence of pseudohyphae confirms *Candida* infection. A video showing a potassium hydroxide examination of a fungal infection is available at <http://www.youtube.com/watch?v=uqeMsyEDJaw>. The Wood



**Figure 3.** Candidal intertrigo in the inguinal fold.

lamp examination fluoresces green with *Pseudomonas* infection and coral-red with erythrasma (Figure 4), a bacterial infection caused by *Corynebacterium minutissimum*.<sup>3</sup>

### Treatment

Table 2 summarizes treatment options for intertrigo.<sup>3,11-18</sup>

#### BARRIER AGENTS

In uncomplicated intertrigo, numerous agents and mechanisms can be used to keep the skin folds dry, clean, and cool. Applying barrier protectants reduces skin breakdown and alleviates pruritus and pain. Skin protectants include zinc oxide ointment and petrolatum.<sup>12</sup> Separating skin surfaces with absorbent products, such as gauze, cotton, and products with water vapor-permeable sheets, may also help reduce friction.

#### DRYING AGENTS

Aluminum sulfate, calcium acetate solution, and antiseptic drying agents (e.g., talcum powder) may be used.<sup>11,13</sup> Powder drying agents should not be applied at the same time as antifungal creams or ointments because this will create a tacky paste. If both are used, they should be applied two to three hours apart. If symptoms do not improve after treatment, potassium hydroxide preparation, and bacterial culture and sensitivity testing should be performed.

#### SECONDARY FUNGAL INFECTIONS

Intertrigo complicated by fungal infection should be managed with topical antifungals. Nystatin is effective only for candidal intertrigo. Clotrimazole, ketoconazole, oxiconazole (Oxistat), or econazole may be used for both *Candida* and dermatophyte infections. Topical treatments are applied twice daily until the rash resolves. Fluconazole (Diflucan), 100 to 200 mg daily for seven days, is used for resistant fungal infections, although patients who are obese may require an increased dosage. Oral azoles may potentiate the effects of hypoglycemic agents, leading to low blood glucose levels, and patients with diabetes should be instructed to monitor their blood glucose levels with concomitant use of these medications.<sup>14</sup>

**Table 1. Differential Diagnosis of Cutaneous Diseases Resembling Intertrigo**

Disease	Characteristics
<b>Infectious diseases</b>	
Candidiasis (moniliasis)	Superficial erythematous infection, commonly affecting moist, cutaneous areas of the skin; satellite pustules
Dermatophytosis (tinea corporis, tinea versicolor)	Pruritic infections of nonviable keratinized tissues, such as nails and hair; contains a leading scale
Erythrasma	Small, red-brown macules that may coalesce into larger patches with sharp borders; may be asymptomatic or pruritic; fluoresces coral-red on Wood lamp examination
Pyoderma	Aggressive infection with boggy, blue-red bullae that progress to deep ulcers with hemorrhagic bases
Scabies	Infection with intense pruritus and minimal cutaneous manifestations, including intertriginous burrows and papules; the head is spared in all age groups except infants
Seborrheic dermatitis	Yellow, greasy, scaly plaques with overlying erythema; most often affects the face, postauricular region, and chest
<b>Noninfectious inflammatory diseases</b>	
Atopic dermatitis	Red or brownish patches with intense pruritus; personal and/or family history of seasonal allergies and asthma is common
Pemphigus vulgaris	Serious, often fatal, autoimmune disease; flaccid bullae, Nikolsky sign (i.e., disruption of the epidermal layer with lateral pressure, leading to ulceration)
Psoriasis	Chronic scaling papules and plaques; often affects extensor surfaces of the elbows and knees; associated with silvery scale
<b>Noninflammatory diseases</b>	
Acanthosis nigricans	Hyperpigmentation with velvety, thickened skin, predominantly on posterior neck and body folds
Hidradenitis suppurativa	Chronic condition of apocrine gland-bearing skin in the axillae or anogenital region; deep abscesses and old scars
Intertrigo	Pruritic regions of erythema and peripheral scaling between skin folds
Lichen sclerosus	Well-demarcated, hypopigmented, atrophic plaques on the genitalia, trunk, and axillae
<b>Neoplasms</b>	
Bowen disease	Solitary, enlarging, erythematous, well-defined plaque
Paget disease	Erythematous plaques with scaling, crusting, and/or exudation; affects the breast, axillae, or anogenital region; may represent a neoplastic process
Superficial basal cell carcinoma	Most common skin cancer; pink or flesh-colored papule often containing a telangiectatic vessel

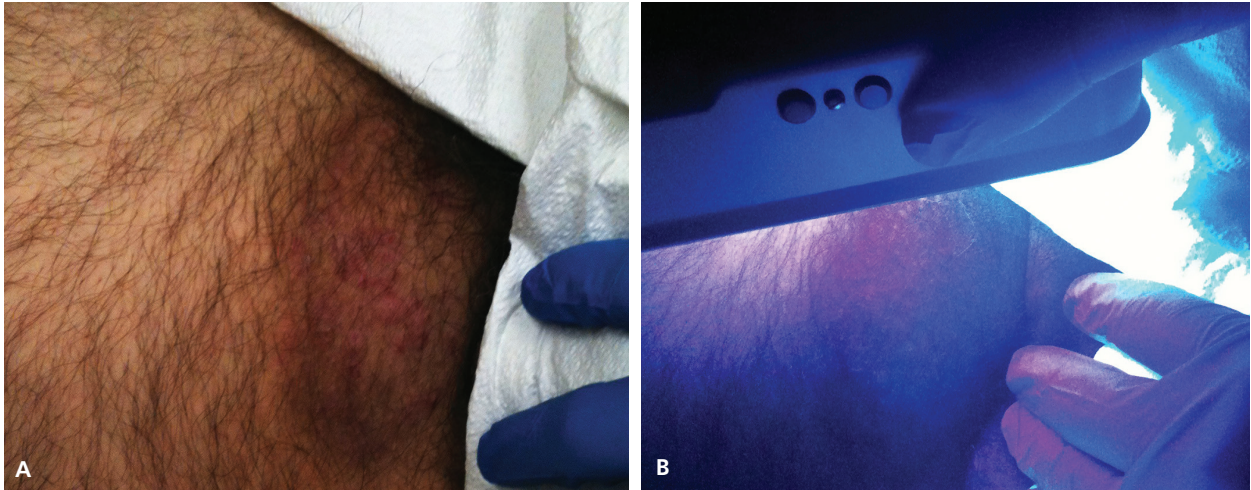
Information from reference 8.

#### SECONDARY BACTERIAL INFECTIONS

The moist, damaged skin associated with intertrigo provides an opportunistic environment for bacterial microorganisms; therefore, secondary cutaneous infections are common. *Staphylococcus aureus* infection may occur independently or with group A beta-hemolytic streptococcal infection.<sup>15</sup> *Pseudomonas aeruginosa*,



## Intertrigo



**Figure 4.** (A) Erythrasma in the inguinal fold appearing as coalesced red-brown macules. (B) Erythrasma lesions fluoresce coral-red on Wood lamp examination.

*Proteus mirabilis*, or *Proteus vulgaris* also may be present independently or simultaneously.

The optimal treatment for patients with intertrigo and group A beta-hemolytic streptococcal infections includes single or multiple regimens of topical therapies

(e.g., mupirocin [Bactroban], erythromycin); oral antibiotics (e.g., penicillin, first-generation cephalosporins); and low-potency topical steroids (e.g., hydrocortisone 1% cream).<sup>3,15</sup> Low-potency topical steroids can also be useful to treat intertrigo associated with seborrheic or atopic dermatitis.<sup>16</sup>

Cutaneous erythrasma is best managed with erythromycin (topical, applied twice daily until rash resolves, or oral, 250 mg four times daily for two weeks).<sup>3,17,18</sup> Oral erythromycin is more effective than a topical regimen, but it can cause adverse reactions, such as nausea, vomiting, abdominal pain, and diarrhea.<sup>3,17,18</sup> Topical clindamycin, Whitfield ointment, and antibiotic soaps may also be beneficial.<sup>17</sup>

### Preventing Recurrent Infections

Keeping the area affected by intertrigo dry and exposed to air can help prevent recurrences. Weight loss should be encouraged if obesity is a predisposing factor. Some patients with large, pendulous breasts may benefit from reduction mammoplasty.<sup>19</sup>

Skin maceration and irritation from incontinence can be minimized or prevented by avoiding or reducing skin exposure to stool or urine. A structured skin care routine based on gentle cleansing, moisturizing (preferably with an emollient), and application of a skin barrier protectant may help.<sup>20,21</sup>

**Table 2. Treatment Options for Inflammatory and Infectious Intertrigo**

Condition	Treatments
Intertrigo	Topical: zinc oxide ointment, petrolatum, talcum powder, aluminum sulfate, calcium acetate solution
Intertrigo complicated by secondary bacterial infections	
Erythrasma	Topical: erythromycin, clindamycin, Whitfield ointment, chlorhexidine Oral: erythromycin
Group A beta-hemolytic streptococcus	Topical: mupirocin (Bactroban), erythromycin, low-potency steroids Oral: penicillin, cephalexin (Keflex), ceftriaxone (Rocephin), cefazolin, clindamycin
Intertrigo complicated by secondary fungal infections	
<i>Candida</i>	Topical: nystatin, clotrimazole, ketoconazole, oxiconazole (Oxistat), econazole Oral: fluconazole (Diflucan; used for resistant cases)
Dermatophytes	Topical: clotrimazole, ketoconazole, oxiconazole, econazole

Information from references 3, and 11 through 18.

**Data Sources:** In conducting our literature search, we used Cochrane, UpToDate, PubMed, and Google Scholar. We used the keywords intertrigo, fungal infections, and secondary skin infections. Search dates: July 2012 and January 2014.

The authors thank Brenda Iyamu, MD; Eric South, DO; and Mark Hand, DO, for their contribution to this article.

## The Authors

MONICA G. KALRA, DO, is research director of the family medicine residency at Methodist Health System of Dallas (Tex.). She is also an assistant professor at the Texas College of Osteopathic Medicine in Fort Worth and a clinical adjunct professor at the University of Texas Southwestern Medical School in Dallas.

KIM E. HIGGINS, DO, is medical director and owner of Physician Senior Services in Dallas. She is also medical director of Envoy Hospice in Fort Worth, Tex.

BRUCE S. KINNEY, DO, is chief resident for the family medicine residency at Methodist Health System of Dallas.

Address correspondence to Monica G. Kalra, DO, Methodist Health System of Dallas, 3500 W. Wheatland, Dallas, TX 75237 (e-mail: monicakalra@mhd.com). Reprints are not available from the authors.

## REFERENCES

1. Scott TD. Intertrigo [handout]. *J Dermatol Nurses Assoc*. 2010;2(5):226.
2. Klenk AS, Martin AG, Heffernan MP. Yeast infections: candidiasis, pityriasis (tinea) versicolor. In: Fitzpatrick TB, Freedberg IM, eds. *Fitzpatrick's Dermatology in General Medicine*. 6th ed. New York, NY: McGraw-Hill; 2003:2006.
3. Janniger CK, Schwartz RA, Szepietowski JC, Reich A. Intertrigo and common secondary skin infections. *Am Fam Physician*. 2005;72(5):833-838.
4. James WD, Elston DM, Berger TG, Andrews GC, eds. *Andrews' Diseases of the Skin: Clinical Dermatology*. 11th ed. London, United Kingdom: Saunders/Elsevier; 2011.
5. Yosipovitch G, DeVore A, Dawn A. Obesity and the skin: skin physiology and skin manifestations of obesity. *J Am Acad Dermatol*. 2007;56(6):901-916.
6. Seale P, Lazar MA. Brown fat in humans: turning up the heat on obesity. *Diabetes*. 2009;58(7):1482-1484.
7. Del Rosso JQ, Draelos ZD, Jorizzo JL, Joseph WS, Ribotsky BM, Rich P. Modern methods to treat superficial fungal disease. *Cutis*. 2007;79(2 suppl):6-29.
8. Fitzpatrick TB, ed. *Color Atlas and Synopsis of Clinical Dermatology: Common and Serious Diseases*. 3rd ed. New York, NY: McGraw-Hill; 1997.
9. Lipsky BA. Medical treatment of diabetic foot infections. *Clin Infect Dis*. 2004;39(suppl 2):S104-S114.
10. Boulton AJ, Vileikyte L, Ragnarson-Tennvall G, Apelqvist J. The global burden of diabetic foot disease. *Lancet*. 2005;366(9498):1719-1724.
11. Guitart J, Woodley DT. Intertrigo: a practical approach. *Compr Ther*. 1994;20(7):402-409.
12. Black JM, Gray M, Bliss DZ, et al. MASD part 2: incontinence-associated dermatitis and intertriginous dermatitis: a consensus. *J Wound Ostomy Continence Nurs*. 2011;38(4):359-370.
13. Sundaram SV, Srinivas CR, Thirumurthy M. Candidal intertrigo: treatment with filter paper soaked in Castellani's paint. *Indian J Dermatol Venereol Leprol*. 2006;72(5):386-387.
14. Habif TP, et al., eds. *Skin Disease: Diagnosis and Treatment*. 3rd ed. Edinburgh, Scotland: Saunders; 2011.
15. Honig PJ, Frieden IJ, Kim HJ, Yan AC. Streptococcal intertrigo: an under-recognized condition in children. *Pediatrics*. 2003;112(6 pt 1):1427-1429.
16. Gupta AK, Madzia SE, Batra R. Etiology and management of seborrheic dermatitis. *Dermatology*. 2004;208(2):89-93.
17. Holdiness MR. Management of cutaneous erythrasma. *Drugs*. 2002;62(8):1131-1141.
18. Stulberg DL, Penrod MA, Blatny RA. Common bacterial skin infections. *Am Fam Physician*. 2002;66(1):119-124.
19. Chadbourne EB, Zhang S, Gordon MJ, et al. Clinical outcomes in reduction mammoplasty: a systematic review and meta-analysis of published studies. *Mayo Clin Proc*. 2001;76(5):503-510.
20. Runeman B. Skin interaction with absorbent hygiene products. *Clin Dermatol*. 2008;26(1):45-51.
21. Gray M. Optimal management of incontinence-associated dermatitis in the elderly. *Am J Clin Dermatol*. 2010;11(3):201-210.