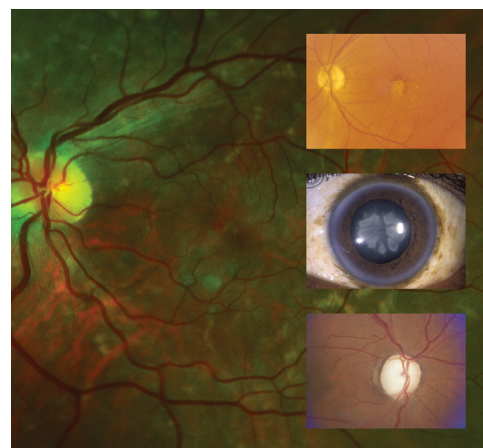


Vision Loss in Older Adults

ALLEN L. PELLETIER, MD; LEDY ROJAS-ROLDAN, MD; and JANIS COFFIN, DO

Medical College of Georgia at Augusta University, Augusta, Georgia

Vision loss affects 37 million Americans older than 50 years and one in four who are older than 80 years. The U.S. Preventive Services Task Force concludes that current evidence is insufficient to assess the balance of benefits and harms of screening for impaired visual acuity in adults older than 65 years. However, family physicians play a critical role in identifying persons who are at risk of vision loss, counseling patients, and referring patients for disease-specific treatment. The conditions that cause most cases of vision loss in older patients are age-related macular degeneration, glaucoma, ocular complications of diabetes mellitus, and age-related cataracts. Vitamin supplements can delay the progression of age-related macular degeneration. Intravitreal injection of a vascular endothelial growth factor inhibitor can preserve vision in the neovascular form of macular degeneration. Medicated eye drops reduce intraocular pressure and can delay the progression of vision loss in patients with glaucoma, but adherence to treatment is poor. Laser trabeculoplasty also lowers intraocular pressure and preserves vision in patients with primary open-angle glaucoma, but long-term studies are needed to identify who is most likely to benefit from surgery. Tight glycemic control in adults with diabetes slows the progression of diabetic retinopathy, but must be balanced against the risks of hypoglycemia and death in older adults. Fenofibrate also slows progression of diabetic retinopathy. Panretinal photocoagulation is the mainstay of treatment for diabetic retinopathy, whereas vascular endothelial growth factor inhibitors slow vision loss resulting from diabetic macular edema. Preoperative testing before cataract surgery does not improve outcomes and is not recommended. (*Am Fam Physician*. 2016;94(3):219-226. Copyright © 2016 American Academy of Family Physicians.)



CME This clinical content conforms to AAFP criteria for continuing medical education (CME). See CME Quiz Questions on page 208.

Author disclosure: No relevant financial affiliations.

► **Patient information:** A handout on this topic is available at <http://familydoctor.org/familydoctor/en/diseases-conditions/vision-loss.html>.

Vision loss is common and consequential among older adults.¹ Family physicians play a critical role in identifying persons who are at risk of vision loss, counseling patients, and referring patients for disease-specific treatment.

The prevalence of all-cause vision loss increases with age, affecting 37 million Americans older than 50 years and 25% of those older than 80 years (*Figure 1*).² Approximately 7% of adults 65 years and older report disability related to impaired vision.³ A 2013 review estimated that the indirect and direct costs of treating adults with visual impairment is \$54 billion annually.⁴ Vision loss in older adults is associated with increased fall risk, loss of independence, depression, and increased all-cause mortality.⁵⁻⁸ Most cases of vision loss in older adults are due to defined diseases for

which there are effective strategies to prevent or delay vision loss and blindness.⁹

Definitions and Legal Issues

Low vision is defined as central visual acuity of 20/70 or worse in the better-seeing eye with best correction or a total visual field loss of 140 degrees. Legal blindness is defined as central visual acuity of 20/200 or worse in the better-seeing eye with best correction or a visual field of 20 degrees or less. Persons with legal blindness may still have adequate vision to maintain activities of daily living and function independently.

A determination of legal blindness may qualify affected persons for Social Security or other disability benefits.¹⁰ A clinical guide to vision assessment in older drivers, including state-specific requirements and counseling recommendations, is available through the American Geriatrics Society.¹¹

SORT: KEY RECOMMENDATIONS FOR PRACTICE

Clinical recommendation	Evidence rating	References
The U.S. Preventive Services Task Force concludes that current evidence is insufficient to assess the balance of benefits and harms of screening for impaired visual acuity in older adults.	C	12
Daily AREDS or AREDS2 vitamin supplementation delays vision loss in patients with age-related macular degeneration.	A	25, 28-31
Intravitreal injection of a vascular endothelial growth factor inhibitor, such as bevacizumab (Avastin), ranibizumab (Lucentis), or aflibercept (Eylea), stabilizes vision in patients with neovascular age-related macular degeneration or diabetic macular edema.	A	33, 36, 37, 53, 54
Fenofibrate (Tricor) reduces the progression of diabetic retinopathy.	A	48, 49
Medical testing before cataract surgery does not improve outcomes and is not recommended.	A	58, 59
Older adults who smoke should be counseled to quit because of an increased risk of vision loss associated with age-related macular degeneration and cataracts.	C	60

AREDS = Age-Related Eye Disease Study.

A = consistent, good-quality patient-oriented evidence; B = inconsistent or limited-quality patient-oriented evidence; C = consensus, disease-oriented evidence, usual practice, expert opinion, or case series. For information about the SORT evidence rating system, go to <http://www.aafp.org/afpsort>.

Screening

The U.S. Preventive Services Task Force (USPSTF) concludes that current evidence is insufficient to assess the balance of benefits and harms of screening for impaired visual acuity in adults older than 65 years. The USPSTF found no well-designed studies demonstrating conclusive benefits of universal eye screening in older adults.¹²

Based on expert consensus, the American Academy of Ophthalmology recommends comprehensive eye examinations every one to two years for all adults 65 years and older.¹³ A comprehensive eye examination includes a visual acuity test, pharmacologic dilation of the pupil, tonometry, and visual field testing.¹⁴

Major Causes

The four major causes of severe vision loss and blindness in older adults are age-related macular degeneration (AMD), ocular complications of diabetes mellitus,

glaucoma, and age-related cataracts.¹⁵ Table 1 summarizes these etiologies.¹⁵⁻²² Refractive error is an important correctable cause of visual impairment, but it is not discussed in this review.

Age-Related Macular Degeneration

Two retinal pigment abnormalities, retinal geographic atrophy and drusen (yellow deposits under the retina made up of lipids), predominate in dry (nonexudative) AMD (Figure 2). Dry AMD can progress to the more severe wet (exudative or neovascular) type (Figure 3), which is characterized by neovascularization and hemorrhage in the macula. In a long-term follow-up study of patients with AMD, 70.9% of participants with bilateral medium drusen at enrollment progressed to large drusen, and 13.8% progressed to advanced AMD over 10 years.²³

The Amsler grid can be used to identify defects in central vision and monitor visual changes in patients with established AMD. Patients are asked to fix their gaze on the black dot in the center and report whether any grid lines appear to be missing or distorted, indicating an abnormality (Figure 4²⁴). New or worsening abnormalities warrant referral to an ophthalmologist.

TREATMENT

Vitamin Supplements. The Age-Related Eye Disease Study (AREDS) is a randomized controlled trial that tested the effectiveness of an antioxidant vitamin supplement in 3,640 patients with AMD who were 55 to 80 years of age.²⁵ Patients in the active treatment arm who had moderate to severe AMD at enrollment had a lower risk of disease progression compared with those receiving placebo over 6.3 years of follow-up (26.7% vs. 35.7%;

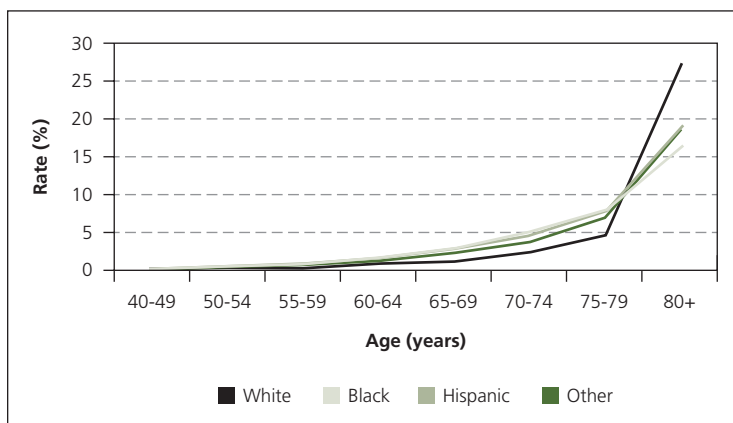


Figure 1. Age-adjusted prevalence of all-cause visual impairment in adults.

Adapted from National Institutes of Health. National Eye Institute. All vision impairment. https://nei.nih.gov/eyedata/vision_impaired. Accessed January 4, 2016.

Table 1. Major Causes of Vision Loss in Older Adults

<i>Disease</i>	<i>Epidemiology</i> ¹⁵	<i>Clinical presentation</i>	<i>Screening recommendations</i>
Age-related cataracts	Cases in U.S. adults 40 years and older (2010): 24.4 million Estimated cases by 2050: 50 million By 75 years of age, 50% of whites will have cataracts in one or both eyes; 70% will have them by 80 years of age 53% of blacks and 61% of Hispanics will be affected by 80 years of age The greatest rate increase by 2050 is expected in Hispanics, with an increase from 1.76 million to 9.51 million	Vision loss Glare intolerance and halos, especially at night or while driving	No specific screening recommendations; treatment is not needed until patients experience bothersome visual symptoms
Age-related macular degeneration	Cases in U.S. adults 50 years and older (2010): 2.44 million Estimated cases by 2050: 5.44 million Affects 2.5% of whites 50 years and older vs. 0.9% of blacks, Hispanics, and persons of other races Risk rises sharply for persons older than 80 years; prevalence among this age group in the United States is 11% overall and 13.8% among whites The greatest rate increase by 2050 will likely be among Hispanics, with a nearly sixfold rise	Vision loss Difficulties with dark adaptation Positive Amsler grid test result	Patients with early age-related macular degeneration or a family history of the disease should be encouraged to assess their own vision (i.e., with an Amsler grid) and to see an ophthalmologist for dilated eye examinations (age to begin screening and optimal examination interval are not specified) ¹⁶
Diabetic eye disease	Cases in U.S. adults (2010): 7.7 million Estimated cases by 2050: 14.6 million Hispanics 50 years and older have the highest rates of diabetic retinopathy, with cases projected to increase from 1.2 million to 5.3 million by 2050	Vision loss Fluctuating vision Presence of floaters Flashes of light (photopsia) Defects in the field of vision	Older adults with diabetes mellitus should be referred to an ophthalmologist at diagnosis for dilated eye examination, and reexamined at least annually ¹⁷ ; it is reasonable to discontinue these examinations in older adults with no or mild diabetic eye disease and life-limiting conditions (e.g., end-stage renal disease)
Glaucoma	Cases in U.S. adults 40 years and older (2010): 2.7 million Estimated cases by 2050: 6.3 million Blacks 40 years and older are at the highest risk By 69 years of age, 6% of U.S. blacks will have glaucoma; risk increases to 12% after 80 years of age	No symptoms in the early stages Peripheral visual field loss and progressive central vision loss become apparent as the disease advances Once established, vision loss is permanent	Current evidence is insufficient to assess the balance of benefits and harms of screening for primary open-angle glaucoma in adults, according to the U.S. Preventive Services Task Force Screening of high-risk groups (e.g., blacks, Hispanics, persons with a family history of glaucoma) should be considered Complete screening includes measurement of visual acuity, measurement of intraocular pressure, and automated visual field testing ¹⁸

Information from references 15 through 22.

number needed to treat = 11).^{25,26} Supplements do not prevent the development of AMD.^{25,27}

Because beta-carotene supplements were subsequently associated with increased lung cancer rates in patients who smoke tobacco, a second trial (AREDS2) randomized participants to a revised supplement containing lutein plus zeaxanthin, omega-3 fatty acids, or both.²⁸⁻³¹ Removal of beta-carotene had no effect on AMD progression.²⁹ Omega-3 fatty acid supplementation offered no benefit beyond the original AREDS formulation.²⁹

Lutein plus zeaxanthin appeared to offer no additional benefit in the general study population.²⁹ Secondary analysis of the subgroup with large drusen at enrollment, however, suggested that lutein plus zeaxanthin may provide modest additional benefit in preventing progression to advanced AMD (hazard ratio = 0.76; 95% confidence interval, 0.61 to 0.96) and development of neovascular AMD (hazard ratio = 0.65; 95% confidence interval, 0.49 to 0.85).^{30,31} Lutein plus zeaxanthin also appears to be safe, with no increased risk of lung cancer.³⁰

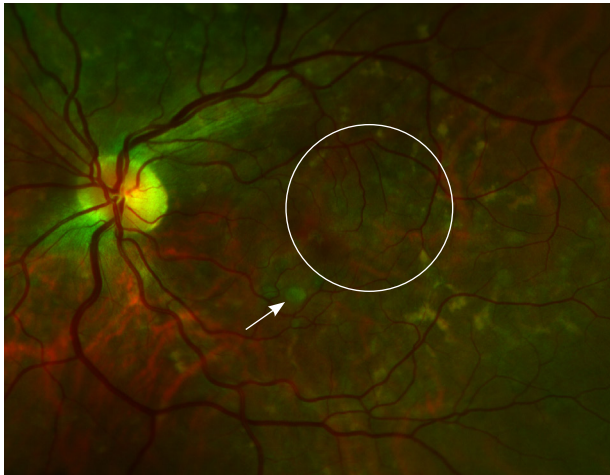


Figure 2. Dry age-related macular degeneration with medium drusen (arrow), and retinal pigment abnormalities (geographic atrophy) in the macula (circle).

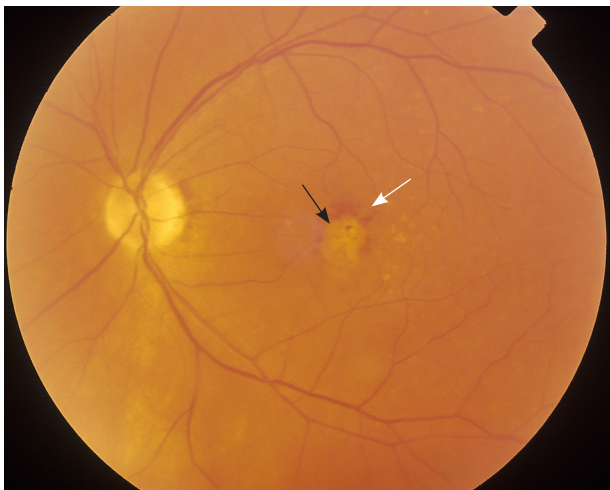

Figure 3. Wet (exudative or neovascular) age-related macular degeneration with confluent drusen (black arrow) in the macula, with surrounding intraretinal macular hemorrhage (white arrow).

The original AREDS and modified AREDS2 formulations (Table 2³²) are sold over the counter. Current or former smokers should be counseled to avoid the original AREDS formula containing beta-carotene.^{29,30}

Vascular Endothelial Growth Factor Inhibitors. The use of vascular endothelial growth factor inhibitors by intravitreal injection is a major advancement in the treatment of neovascular AMD.³³ Injections are administered once monthly for four months or until vision stabilizes, then every three months thereafter. The safety and effectiveness of this intervention have not been evaluated past 24 months.

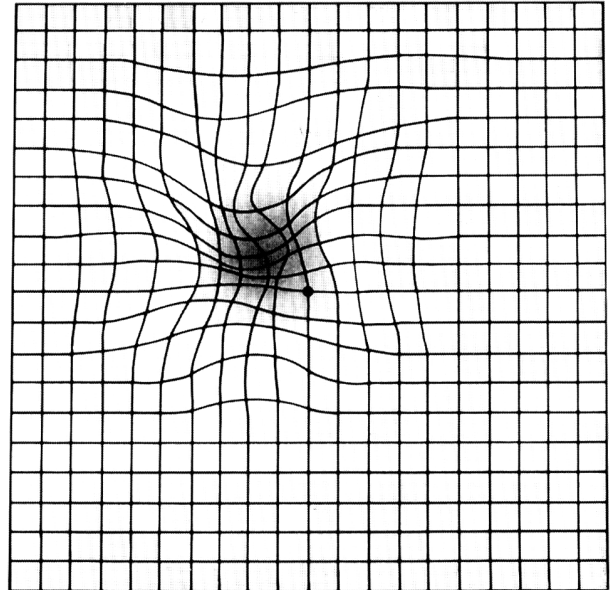


Figure 4. Amsler grid, as seen by an individual with macular degeneration.

Reprinted from National Institutes of Health. National Eye Institute. Distorted Amsler grid. <https://www.flickr.com/photos/nationaleyeinstitute/7544605480>. Accessed January 4, 2016.

Ranibizumab (Lucentis) and bevacizumab (Avastin) appear to be slightly more effective than pegaptanib (Macugen), with similar adverse effect and safety profiles.³³ Pegaptanib, ranibizumab, and aflibercept (Eylea) are approved by the U.S. Food and Drug Administration (FDA) for the treatment of neovascular AMD. Bevacizumab has to be compounded for intravitreal injection and is not FDA approved for AMD treatment. The cost of bevacizumab is significantly lower per dose than other, FDA-approved agents (approximately \$150 vs. \$1,500 to \$2,000). Many ophthalmologists favor using the less-expensive bevacizumab instead of ranibizumab, citing comparable safety and effectiveness; however, the manufacturer, which produces both drugs, has not sought FDA approval for bevacizumab.³⁴

A contaminated lot of compounded bevacizumab caused 12 cases of severe eye infection in 2011.³⁵ Excluding this outbreak, which was traced to a single compounding supplier, bevacizumab has a similar safety profile to the other, FDA-approved agents.^{36,37}

Glaucoma

CLASSIFICATION AND DIAGNOSIS

Glaucoma is a heterogeneous group of ophthalmic conditions that cause progressive damage to the optic nerve, leading to visual field loss and irreversible blindness

Table 2. Supplements to Delay Progression of Age-Related Macular Degeneration

AREDS supplements	AREDS2 supplements
500 mg vitamin C	500 mg vitamin C
400 IU vitamin E	400 IU vitamin E
15 mg beta-carotene*	25 mg zinc
80 mg zinc as zinc oxide	2 mg copper as cupric oxide
2 mg copper as cupric oxide	10 mg lutein plus 2 mg zeaxanthin

AREDS = Age-Related Eye Disease Study.

*—Associated with increased rates of lung cancer in smokers.

Information from reference 32.

(Figure 5). Primary open-angle glaucoma and primary angle-closure glaucoma are the most common forms. Most patients with glaucoma have ocular hypertension (elevated intraocular pressure), but optic nerve damage can also occur with normal intraocular pressure.³⁸ Diagnosis requires measurement of intraocular pressure in conjunction with evaluation of the optic disc and an automated visual field test.^{18,38}

SCREENING AND PREVENTION

The USPSTF found insufficient evidence to assess the balance of benefits and harms of screening for primary open-angle glaucoma, but recognizes that certain subpopulations (e.g., persons with a family history of glaucoma,

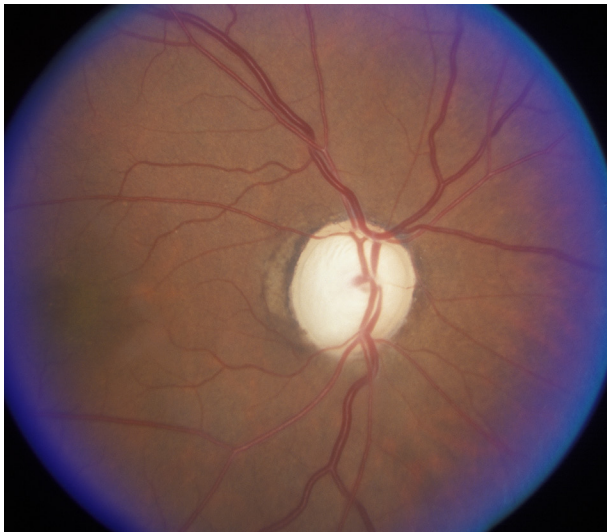

Figure 5. Advanced glaucoma. Typical features include enlarged, pale optic disc and increased cup/disc ratio.

blacks, Hispanics) are at higher risk of the disease and may be more likely to benefit from referral for periodic intraocular pressure measurement and automated visual field testing.¹⁸

TREATMENT

A number of medicated eye drops lower intraocular pressure and can delay the progression of vision loss.^{1,39} Long-term adherence to therapy remains a major problem; continuation rates are typically less than 50% at one year.⁴⁰ Simplifying eye drop regimens, providing patient education, coaching on proper eye drop technique, and offering ongoing support to patients may improve adherence.⁴¹

Because adherence to medical therapy for glaucoma is poor, there is interest in surgical approaches to stop progression of glaucoma before vision loss becomes irreversible. Laser trabeculoplasty for primary open-angle glaucoma appears to be safe and effective in lowering intraocular pressure and preserving vision.⁴² Long-term studies are needed to identify which patients are most likely to benefit from surgery, the optimal technique, and the effectiveness of repeat procedures.

Diabetic Eye Disease

SCREENING AND MONITORING

Older adults with type 2 diabetes should be referred to an ophthalmologist at diagnosis for dilated eye examination, and reexamined at least annually.¹⁷ It is reasonable to discontinue these examinations in older adults with no or mild diabetic eye disease and life-limiting conditions (e.g., end-stage renal disease).

SLOWING DISEASE PROGRESSION

Glycemic Control. Several large clinical trials have demonstrated that tight glycemic control decreases the risk of progression of diabetic retinopathy.⁴³⁻⁴⁵ It is unclear how these results apply to the care of older adults with diabetes, who often have multiple comorbidities that complicate diabetes management and are at risk of hypoglycemia and increased all-cause mortality with tight glycemic control.^{46,47} The American Diabetes Association revised consensus guidelines recommend individualized adjustment of A1C goals (target range of 8.5%) in older adults.⁴³

Fenofibrate. Two large clinical trials have demonstrated that fenofibrate (Tricor) increases the time to first laser treatment and slows the overall progression of diabetic retinopathy, regardless of its effect on plasma lipid levels.^{48,49}

TREATMENT OF PROGRESSIVE DIABETIC RETINOPATHY

Photocoagulation. Nonproliferative diabetic retinopathy with preserved visual acuity can be monitored without

**BEST PRACTICES IN OPHTHALMOLOGY:
RECOMMENDATIONS FROM THE CHOOSING WISELY
CAMPAIGN**

Recommendation	Sponsoring organization
Do not perform preoperative medical tests for eye surgery unless there are specific medical indications.	American Academy of Ophthalmology

Source: For more information on the Choosing Wisely Campaign, see <http://www.choosingwisely.org>. For supporting citations and to search Choosing Wisely recommendations relevant to primary care, see <http://www.aafp.org/afp/recommendations/search.htm>.

active treatment. Widespread neovascularization and hemorrhage indicate progression to proliferative diabetic retinopathy (Figure 6), which requires treatment, typically with panretinal photocoagulation.⁵⁰

Vascular endothelial growth factor inhibitors. Based on low-quality evidence, a Cochrane review concluded that vascular endothelial growth factor inhibitors have limited effectiveness for proliferative diabetic retinopathy.⁵¹ However, they may have a role if standard therapy is ineffective or vitreous hemorrhage occurs.⁵²

TREATMENT OF DIABETIC MACULAR EDEMA

Diabetic macular edema causes rapid vision deterioration and can quickly lead to blindness. Aflibercept, bevacizumab, and ranibizumab have been studied for diabetic macular edema with comparable effectiveness, adverse effects, and safety profiles.^{53,54} Aflibercept and ranibizumab were approved by the FDA for the treatment of diabetic macular edema in 2015. Bevacizumab is not approved for use in diabetic macular edema. Patients who are treated with any of these agents demonstrate significantly better vision (a gain of three or more lines of vision on the Snellen chart) than individuals treated with laser photocoagulation. Aflibercept may offer a slight advantage in more advanced cases of diabetic macular edema.⁵³

Intravitreal administration of corticosteroids, either by injection or implant, is another treatment option. A Cochrane review found that this therapy had a beneficial effect in stopping the progression of diabetic macular edema, but led to greater risk of increased intraocular pressure and cataract formation.⁵⁵

Age-Related Cataracts

DIAGNOSIS

Cataracts can be readily detected with a handheld ophthalmoscope. The red reflex appears dull, extinct, or shady in a patient with cataracts (Figure 7). Treatment is not needed for cataracts that do not cause significant visual impairment. Impaired vision, glare sensitivity, or difficulty with nighttime vision (especially when driving) warrants referral to an ophthalmologist.

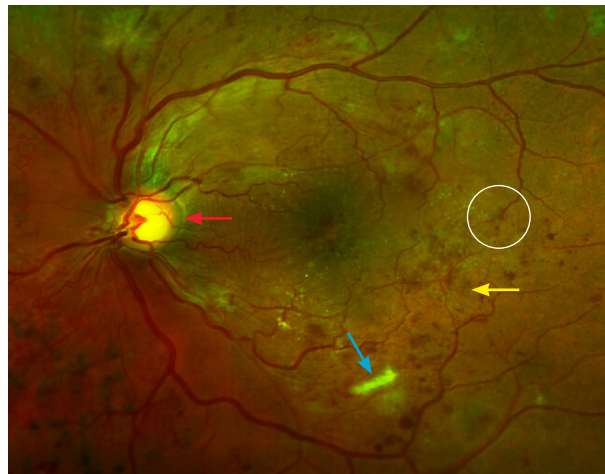


Figure 6. Proliferative diabetic retinopathy with hard exudates (blue arrow), aneurysm (circle), intraretinal hemorrhages (yellow arrow), and neovascularization (red arrow).

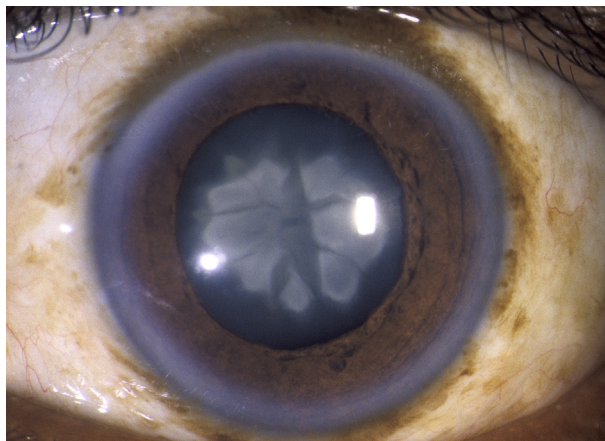


Figure 7. Nuclear cataract viewed through a slit lamp.

TREATMENT

Surgery is the only effective treatment for a cataract that compromises vision. Phacoemulsification with intraocular lens replacement is the standard surgical approach in the United States.⁵⁶

Immediate sequential cataract surgery (surgery on both eyes during the same visit) has been researched for its cost-saving potential vs. the more common delayed sequential cataract surgery. A study of Medicare beneficiaries in west Tennessee projected that Medicare would save \$522 million per year nationally if immediate sequential cataract surgery were widely adopted.⁵⁷

A Cochrane review of three clinical trials found that routine medical testing before cataract surgery does not improve outcomes.⁵⁸ The American Academy of Ophthalmology recommends against routine preoperative medical testing.⁵⁹

PREVENTION

Ultraviolet light exposure and smoking are associated with accelerated cataract formation.^{60,61} It is reasonable

to counsel older patients to reduce their exposure to ultraviolet light when feasible and to stop smoking. Smoking is also linked to an increased risk of vision loss associated with age-related macular degeneration.⁶¹ Supplements such as those used in the AREDS do not prevent or slow the progression of cataracts.⁶²

Data Sources: Searches were performed in Pub Med, Healthy People 2020 Structured Evidence Queries (Vision), Essential Evidence Plus, National Guideline Clearinghouse, U.S. Preventive Services Task Force recommendations, Cochrane Database of Systematic Reviews, and the website of the National Eye Institute of the National Institutes of Health. Search terms included eye disease, eye disease in older adults, vision loss, low vision, blindness, and disease-specific terms, including age-related macular degeneration, diabetic eye disease, diabetic retinopathy, glaucoma, ocular hypertension, and age-related cataracts. Search dates: October 2015, December 2015, and May 2016.

Figures 2, 3, 5, 6, and 7 courtesy of Mike Stanley, Department of Ophthalmology, Augusta University.

This review updates a previous article on this topic by Pelletier, et al.¹

The Authors

ALLEN L. PELLETIER, MD, is a professor in the Department of Family Medicine at the Medical College of Georgia at Augusta University.

LEDY ROJAS-ROLDAN, MD, is an assistant professor in the Department of Family Medicine at the Medical College of Georgia at Augusta University.

JANIS COFFIN, DO, is an associate professor in the Department of Family Medicine at the Medical College of Georgia at Augusta University.

Address correspondence to Allen L. Pelletier, MD, Medical College of Georgia, HB 4020, Augusta, GA 30912 (e-mail: apelletier@augusta.edu). Reprints are not available from the authors.

REFERENCES

- Pelletier AL, Thomas J, Shaw FR. Vision loss in older persons. *Am Fam Physician*. 2009;79(11):963-970.
- National Institutes of Health. National Eye Institute. All vision impairment. https://nei.nih.gov/eyedata/vision_impaired. Accessed January 4, 2016.
- Courtney-Long EA, Carroll DD, Zhang QC, et al. Prevalence of disability and disability type among adults—United States, 2013. *MMWR Morb Mortal Wkly Rep*. 2015;64(29):777-783.
- Cardarelli WJ, Smith RA. Managed care implications of age-related ocular conditions. *Am J Manag Care*. 2013;19(5 suppl):S85-S91.
- Dhital A, Pey T, Stanford MR. Visual loss and falls: a review. *Eye (Lond)*. 2010;24(9):1437-1446.
- Senra H, Barbosa F, Ferreira P, et al. Psychologic adjustment to irreversible vision loss in adults: a systematic review. *Ophthalmology*. 2015;122(4):851-861.
- Pedula KL, Coleman AL, Yu F, et al.; Study of Osteoporotic Fractures Research Group. Age-related macular degeneration and mortality in older women: the study of osteoporotic fractures. *J Am Geriatr Soc*. 2015;63(5):910-917.
- Soubrane G, Cruess A, Lotery A, et al. Burden and health care resource utilization in neovascular age-related macular degeneration: findings of a multicountry study. *Arch Ophthalmol*. 2007;125(9):1249-1254.
- Bourne RR, Stevens GA, White RA, et al; Vision Loss Expert Group. Causes of vision loss worldwide, 1999-2010: a systematic analysis. *Lancet Glob Health*. 2013;1(6):e339-e349.
- Social Security Administration. If you're blind or have low vision—how we can help. 2016. <http://www.ssa.gov/pubs/EN-05-10052.pdf>. Accessed January 4, 2016.
- American Geriatrics Society. Clinician's guide to assessing and counseling older drivers. <http://geriatricscareonline.org/ProductAbstract/clinician-s-guide-to-assessing-and-counseling-older-drivers/B022>. Accessed December 1, 2015.
- Siu AL, Bibbins-Domingo K, Grossman DC, et al. Screening for impaired visual acuity in older adults: U.S. Preventive Services Task Force recommendation statement. *JAMA*. 2016;315(9):908-914.
- Feder RS, Olsen TW, Prum BE Jr, et al. Comprehensive adult medical eye evaluation Preferred Practice Pattern® guidelines. *Ophthalmology*. 2016;123(1):P209-P236.
- National Institutes of Health. National Eye Institute. What is a comprehensive dilated eye exam? <https://nei.nih.gov/healthyeyes/eyeexam>. Accessed January 2, 2016.
- Prevent Blindness America. Vision problems in the U.S.: prevalence of adult vision impairment and age-related eye disease in America. <http://www.visionproblemsus.org/>. Accessed January 4, 2016.
- American Academy of Ophthalmology. Age-related macular degeneration PPP - updated 2015. <http://www.aao.org/preferred-practice-pattern/age-related-macular-degeneration-ppp-2015>. Accessed December 1, 2015.
- American Academy of Ophthalmology Retina/Vitreous Panel. Preferred Practice Pattern guidelines. Diabetic retinopathy. 2014. <http://www.aao.org/preferred-practice-pattern/diabetic-retinopathy-ppp-updated-2016>. Accessed May 25, 2016.
- U.S. Preventive Services Task Force. Glaucoma: screening. Final recommendation statement. July 2013. <http://www.uspreventiveservicestaskforce.org/Page/Document/RecommendationStatementFinal/glaucoma-screening>. Accessed January 4, 2016.
- National Institutes of Health. National Eye Institute. Facts about age-related macular degeneration. https://nei.nih.gov/health/macularden/gen/armd_facts. Accessed October 1, 2015.
- National Institutes of Health National Eye Institute. Facts about diabetic eye disease. <https://nei.nih.gov/health/diabetic/retinopathy>. Accessed October 1, 2015.
- National Institutes of Health. National Eye Institute. Facts about glaucoma. https://nei.nih.gov/health/glaucoma/glaucoma_facts. Accessed October 1, 2015.
- National Institutes of Health. National Eye Institute. Facts about cataract. https://nei.nih.gov/health/cataract/cataract_facts. Accessed October 1, 2015.
- Chew EY, Clemons TE, Agrón E, et al.; Age-Related Eye Disease Study Research Group. Ten-year follow-up of age-related macular degeneration in the Age-Related Eye Disease Study: AREDS report no. 36. *JAMA Ophthalmol*. 2014;132(3):272-277.
- National Institutes of Health. National Eye Institute. Distorted Amsler grid. <https://www.flickr.com/photos/nationaleyeinstitute/7544605480>. Accessed January 4, 2016.
- Age-Related Eye Disease Study Research Group. A randomized, placebo-controlled, clinical trial of high-dose supplementation with vitamins C and E, beta carotene, and zinc for age-related macular degeneration and vision loss: AREDS report no. 8. *Arch Ophthalmol*. 2001;119(10):1417-1436.
- Gordon JE, Schooff M. Can high-dose supplementation with vitamins C and E, beta carotene, and zinc slow the progression of macular degeneration? *J Fam Pract*. 2002;51(2):105.
- Evans JR, Lawrenson JG. Antioxidant vitamin and mineral supplements for preventing age-related macular degeneration. *Cochrane Database Syst Rev*. 2012;(6):CD000253.
- Chew EY, Clemons T, SanGiovanni JP, et al.; AREDS2 Research Group. The Age-Related Eye Disease Study 2 (AREDS2): study design and baseline characteristics (AREDS2 report number 1). *Ophthalmology*. 2012;119(11):2282-2289.

Vision Loss in Older Adults

29. Age-Related Eye Disease Study 2 Research Group. Lutein + zeaxanthin and omega-3 fatty acids for age-related macular degeneration: the Age-Related Eye Disease Study 2 (AREDS2) randomized clinical trial [published correction appears in *JAMA*. 2013;310(2):208]. *JAMA*. 2013;309(19):2005-2015.
30. Chew EY, Clemons TE, Sangiovanni JP, et al.; Age-Related Eye Disease Study 2 (AREDS2) Research Group. Secondary analyses of the effects of lutein/zeaxanthin on age-related macular degeneration progression: AREDS2 report no. 3. *JAMA Ophthalmol*. 2014;132(2):142-149.
31. Aronow ME, Chew EY. Age-related Eye Disease Study 2: perspectives, recommendations, and unanswered questions. *Curr Opin Ophthalmol*. 2014;25(3):186-190.
32. National Institutes of Health. National Eye Institute. Macular degeneration. AREDS and AREDS2. https://answers.nei.nih.gov/app/answers/detail/a_id/2470/~-/macular-degeneration-|-areds-and-areds2. Accessed May 17, 2016.
33. Solomon SD, Lindsley K, Vedula SS, Krzystalik MG, Hawkins BS. Anti-vascular endothelial growth factor for neovascular age-related macular degeneration. *Cochrane Database Syst Rev*. 2014;(8):CD005139.
34. Haddrill M. Lucentis vs. avastin: a macular degeneration treatment controversy. <http://www.allaboutvision.com/conditions/lucentis-vs-avastin.htm>. Accessed January 4, 2016.
35. Goldberg RA, Flynn HW Jr, Isom RF, Miller D, Gonzalez S. An outbreak of streptococcus endophthalmitis after intravitreal injection of bevacizumab. *Am J Ophthalmol*. 2012;153(2):204-208.e1.
36. Moja L, Lucenteforte E, Kwag KH, et al. Systemic safety of bevacizumab versus ranibizumab for neovascular age-related macular degeneration. *Cochrane Database Syst Rev*. 2014;(9):CD011230.
37. Tufail A, Patel PJ, Egan C, et al.; ABC Trial Investigators. Bevacizumab for neovascular age related macular degeneration (ABC Trial): multicentre randomised double masked study. *BMJ*. 2010;340:c2459.
38. Quigley HA. Glaucoma. *Lancet*. 2011;377(9774):1367-1377.
39. Kass MA, Heuer DK, Higginbotham EJ, et al. The Ocular Hypertension Treatment Study: a randomized trial determines that topical ocular hypotensive medication delays or prevents the onset of primary open-angle glaucoma. *Arch Ophthalmol*. 2002;120(6):701-713.
40. Schwartz GF, Quigley HA. Adherence and persistence with glaucoma therapy. *Surv Ophthalmol*. 2008;53(suppl 1):S57-S68.
41. Waterman H, Evans JR, Gray TA, Henson D, Harper R. Interventions for improving adherence to ocular hypotensive therapy. *Cochrane Database Syst Rev*. 2013;(4):CD006132.
42. Samples JR, Singh K, Lin SC, et al. Laser trabeculoplasty for open-angle glaucoma: a report by the American Academy of Ophthalmology. *Ophthalmology*. 2011;118(11):2296-2302.
43. Kirkman MS, Briscoe VJ, Clark N, et al. Diabetes in older adults. *Diabetes Care*. 2012;35(12):2650-2664.
44. Stratton IM, Kohner EM, Aldington SJ, et al. UKPDS 50: risk factors for incidence and progression of retinopathy in type II diabetes over 6 years from diagnosis. *Diabetologia*. 2001;44(2):156-163.
45. Holman RR, Paul SK, Bethel MA, Matthews DR, Neil HA. 10-year follow-up of intensive glucose control in type 2 diabetes. *N Engl J Med*. 2008;359(15):1577-1589.
46. Chew EY, Ambrosius WT, Davis MD, et al.; ACCORD Study Group; ACCORD Eye Study Group. Effects of medical therapies on retinopathy progression in type 2 diabetes [published corrections appear in *N Engl J Med*. 2011;364(2):190 and *N Engl J Med*. 2012;367(25):2458]. *N Engl J Med*. 2010;363(3):233-244.
47. Gerstein HC, Miller ME, Genuth S, et al.; ACCORD Study Group. Long-term effects of intensive glucose lowering on cardiovascular outcomes. *N Engl J Med*. 2011;364(9):818-828.
48. Keech AC, Mitchell P, Summanen PA, et al.; FIELD study investigators. Effect of fenofibrate on the need for laser treatment for diabetic retinopathy (FIELD study): a randomised controlled trial. *Lancet*. 2007;370(9600):1687-1697.
49. Wong TY, Simó R, Mitchell P. Fenofibrate - a potential systemic treatment for diabetic retinopathy? *Am J Ophthalmol*. 2012;154(1):6-12.
50. Evans JR, Michelessi M, Virgili G. Laser photocoagulation for proliferative diabetic retinopathy. *Cochrane Database Syst Rev*. 2014;(11):CD011234.
51. Martinez-Zapata MJ, Marti-Carvajal AJ, Solà I, et al. Anti-vascular endothelial growth factor for proliferative diabetic retinopathy. *Cochrane Database Syst Rev*. 2014;(11):CD008721.
52. Osaadon P, Fagan XJ, Lifshitz T, Levy J. A review of anti-VEGF agents for proliferative diabetic retinopathy. *Eye (Lond)*. 2014;28(5):510-520.
53. Wells JA, Glassman AR, Ayala AR, et al.; Diabetic Retinopathy Clinical Research Network. Aflibercept, bevacizumab, or ranibizumab for diabetic macular edema. *N Engl J Med*. 2015;372(13):1193-1203.
54. Virgili G, Parravano M, Menchini F, Evans JR. Anti-vascular endothelial growth factor for diabetic macular oedema. *Cochrane Database Syst Rev*. 2014;(10):CD007419.
55. Grover D, Li TJ, Chong CC. Intravitreal steroids for macular edema in diabetes. *Cochrane Database Syst Rev*. 2008;(1):CD005656.
56. Riaz Y, Mehta JS, Wormald R, et al. Surgical interventions for age-related cataract. *Cochrane Database Syst Rev*. 2006;(4):CD001323.
57. Neel ST. A cost-minimization analysis comparing immediate sequential cataract surgery and delayed sequential cataract surgery from the payer, patient, and societal perspectives in the United States. *JAMA Ophthalmol*. 2014;132(11):1282-1288.
58. Keay L, Lindsley K, Tielsch J, Katz J, Schein O. Routine preoperative medical testing for cataract surgery. *Cochrane Database Syst Rev*. 2012;(3):CD007293.
59. American Academy of Ophthalmology. Routine preoperative laboratory testing for patients scheduled for cataract surgery—2014. <http://www.aao.org/clinical-statement/routine-preoperative-laboratory-testing-patients-s>. Accessed January 4, 2016.
60. Galor A, Lee DJ. Effects of smoking on ocular health. *Curr Opin Ophthalmol*. 2011;22(6):477-482.
61. Roberts JE. Ultraviolet radiation as a risk factor for cataract and macular degeneration. *Eye Contact Lens*. 2011;37(4):246-249.
62. Chew EY, SanGiovanni JP, Ferris FL; The Age Related Eye Disease Study 2 (AREDS2) Research Group. Lutein/zeaxanthin for the treatment of age-related cataract. AREDS2 randomized trial report no. 4. *JAMA Ophthalmol*. 2013;131(7):843-850.